



# *Coloproctology 2014*

*(International Scientific Congress)*

*6<sup>th</sup> to 9<sup>th</sup> March 2014*

*Shangri-La Hotel  
Kuala Lumpur, Malaysia*

*Souvenir Programme & Abstract book*

## MAJOR SPONSORS





## CONTENTS

Malaysian Society of Colorectal Surgeons – Office Bearers 2013 – 2015 Organising Committee	2
Welcome Message from the President, Malaysian Society of Colorectal Surgeons & Organising Chairman, Coloproctology 2014	3
Programme Summary	4
Pre-Congress Operative Workshop	5
Daily Programme	6 – 10
Postgraduate Round Post-Congress Workshop	11
Conference Information	12
Function Rooms & Trade Exhibition	13
Acknowledgements	14
Abstracts	15 – 61
• Scientific Papers	(15 – 33)
• Best Poster Award Presentations / Poster Presentations	(34 – 61)



## MALAYSIAN SOCIETY OF COLORECTAL SURGEONS OFFICE BEARERS 2013 – 2015

President	Dr Lu Ping Yan
Past President	Dato' Dr Wan Khamizar Wan Khazim
Vice President	Prof Dr Azmi Md Nor
Hon Secretary	Assoc Prof Datuk Dr Ismail Sagap
Hon Treasurer	Assoc Prof Dr April Camilla Roslani
Council Members	Dr Jasiah Zakaria Dato' Dr Meheshinder Singh

## ORGANISING COMMITTEE

Chairman	Dr Lu Ping Yan
Deputy Chairman	Dato' Dr Wan Khamizar Wan Khazim
Hon Secretary	Dr Jasiah Zakaria
Scientific Committee	Prof Dr Azmi Md Nor (Chairman) Assoc Prof Dr April Camilla Roslani Dr Akhtar Qureshi Datuk Dr Yunus Gul
Pre-Congress Workshop	Assoc Prof Datuk Dr Ismail Sagap
Allied Health Professional Programme	Dato' Dr Meheshinder Singh Dr M Sarkunna Thas Ms Mariam Hj Mohd Nasir
Business Managers	Dr Samuel Tay Dr Paul Selvindoss
Social	Dr Manohar Padmanathan
Publicity	Dr Ahmad Shanwani





## WELCOME MESSAGE



The Organising Committee warmly welcomes all delegates to Coloproctology 2014!

The topics in the scientific programme for Coloproctology 2014 have been carefully selected to include common colorectal problems encountered by colorectal and general surgeons in daily practice. A whole spectrum of colorectal diseases – from perianal disorders, colorectal emergencies, colorectal cancers to inflammatory bowel disease – has been covered. All these will be deliberated in plenaries, symposia, panel discussions, “How I Do It” session, and Professors’ Corner.

The Allied Health Professional programme has also been structured to address the important areas relevant to the nursing, enterostomal and supportive care of patients with colorectal diseases.

As usual, there will be a Pre-Congress Operative Workshop where eminent overseas and local surgeons will demonstrate interesting operations live. Furthermore, there will be a Post-Congress Workshop on Inflammatory Bowel Disease, organised in collaboration with the Malaysian Society of Gastroenterology and Hepatology.

For postgraduate trainees, there will be an annual Postgraduate Round which many postgraduate, as well as undergraduate doctors, have found to be very useful in the past.

A special feature in the programme is that, for the first time, the Malaysian Society of Colorectal Surgeons is concurrently running a symposium jointly with the Colorectal Cancer Survivorship Society Malaysia. The idea for this symposium was first mooted by Dato’ Dr Meheshinder Singh. The objective of this symposium is for the Malaysian Society of Colorectal Surgeons to work with the Colorectal Cancer Survivorship Society Malaysia to address healthcare and other relevant issues pertinent to survivors of colorectal cancer.

Last but not least, we hope you will have time to experience the culture, food, interesting places and hospitality that the city of Kuala Lumpur has to offer!

**DR LU PING YAN**

President, MSCRS &  
Organising Chairman, Coloproctology 2014



## PROGRAMME SUMMARY

Time	Date	7 <sup>th</sup> March 2014, Friday		8 <sup>th</sup> March 2014, Saturday		
0830 – 0900		Sabah Room	Kedah / Selangor Room	Sabah Room	Kedah / Selangor Room	
0900 – 0930		SYMPOSIUM 1	SYMPOSIUM 2 Allied Health Professional Session (1)	SYMPOSIUM 6	SYMPOSIUM 7 Allied Health Professional Session (3)	SYMPOSIUM 8 Colorectal Cancer Survivorship Session (1) Panel Discussion
0930 – 1000						
1000 – 1030				Tea		
1030 – 1100		Sabah Room	Tea	PLENARY 3	Tea	
1100 – 1130			Kedah / Selangor Room	Tea		
1130 – 1200		Sabah Room	SYMPOSIUM 4 Allied Health Professional Session (2)	Sabah Room	SYMPOSIUM 10 Allied Health Professional Session (4)	SYMPOSIUM 11 Colorectal Cancer Survivorship Session (2)
1200 – 1230				SYMPOSIUM 9		
1230 – 1300		LUNCH SATELLITE SYMPOSIUM (Johnson & Johnson)		LUNCH SATELLITE SYMPOSIUM (Sanofi-Aventis)		
1300 – 1330		Lunch		Lunch		
1330 – 1400		Friday Prayers		Lunch		
1400 – 1430		Sabah Room	Kedah / Selangor Room	Sabah Room	Kedah / Selangor Room	
1430 – 1500		PLENARY 2	(1400 – 1700)	PLENARY 4	(1400 – 1700)	PERAK ROOM (1430 – 1630)
1500 – 1530		Sabah Room	PRESENTATIONS BY COMPANIES AND WORKSHOP Allied Health Professional Session	Sabah Room	PRESENTATIONS BY COMPANIES AND WORKSHOP Allied Health Professional	ROUND TABLE DISCUSSION Colorectal Cancer Survivorship
1530 – 1600		SYMPOSIUM 5		PANEL DISCUSSION		
1600 – 1630				Sabah Room		
1630 – 1700		Sabah Room		PROFESSORS' CORNER		
1700 – 1730		HOW I DO IT (incorporating Tea)				Tea
1730 – 1800						PERAK ROOM (1645 – 1800)
1800 – 1900		PERAK ROOM				CORUM AGM
1930 – 2200		GALA DINNER				

6 <sup>th</sup> March 2014, Thursday
0800 – 1700 PRE-CONGRESS OPERATIVE WORKSHOP Venue: Advanced Surgical Skills Centre Universiti Kebangsaan Malaysia Kuala Lumpur

9 <sup>th</sup> March 2014, Sunday	
0900 – 1200 POSTGRADUATE ROUND Venue: Universiti Kebangsaan Malaysia Kuala Lumpur	0800 – 1300 POST-CONGRESS WORKSHOP 'Bridging The Gap' – Multidisciplinary Management of Inflammatory Bowel Disease Venue: Perak & Selangor Shangri-La Hotel, KL



## PRE-CONGRESS OPERATIVE WORKSHOP 6<sup>th</sup> March 2014, Thursday

Time : 0800 – 1700 hrs  
Venue : Advanced Surgical Skills Centre, Universiti Kebangsaan Malaysia, Kuala Lumpur  
Faculty : Pradeep Chowbey (India)  
Thomas Deska (Germany)  
Alessandro Fichera (USA)  
Eiji Kanehira (Japan)  
Shailesh Puntambekar (India)  
Charles Tsang (Singapore)

### Programme

- 0800 – 0825** Registration
- 0830 – 0835** Welcoming speech by Chairman Pre-Congress Surgical Workshop for Coloproctology 2014,  
Datuk Ismail Sagap
- 0840 – 1030** OT4: Laparoscopic Panproctocolectomy with Ileal Pouch-Anal Anastomosis  
Alessandro Fichera  
OT5: Laparoscopic Sigmoid Colectomy  
Shailesh Puntambekar
- 1045 – 1100** Tea
- 1100 – 1300** OT4: Trans Anal Minimally Invasive Surgery  
Eiji Kanehira  
OT5: Endo-Anal Ultrasound  
Charles Tsang  
LASER Anal Fistula Surgery  
Thomas Deska
- 1300 – 1400** Lunch
- 1400 – 1645** OT4: Endo-Anal Ultrasound  
Charles Tsang  
Video-assisted Anal Fistula Treatment (VAAFT)  
Pradeep Chowbey  
OT5: LASER Haemorrhoidopexy  
Thomas Deska
- 1645 – 1700** Closing / Tea



## DAILY PROGRAMME

### 7<sup>th</sup> March 2014, Friday

0830 – 1015

#### **SYMPOSIUM 1**

Sabah Room

Complex Fistula

*Chairpersons: Azmi Md Nor / Ahmad Shanwani*

Anatomy of fistula-in-ano [pg 15]

Arun Rojanasakul

Complex fistula-in-ano

- Assessment of complex fistula-in-ano using MRI

Abdul Samad Sakijan

- Assessment of complex fistula-in-ano using EUS

Charles Tsang

Management of complex fistula-in-ano [pg 16]

Arun Rojanasakul

VAAFT – How I do it

Pradeep Chowbey

1015 – 1030

Tea / Official Poster Round

1030 – 1115

#### **PLENARY 1**

Sabah Room

*Chairperson: April Roslani*

Challenges in IBD [pg 17]

Alessandro Fichera

1115 - 1215

#### **SYMPOSIUM 3**

Sabah Room

Recent Advances in Detection of Colorectal Cancers

*Chairpersons: Jasiah Zakaria / Gooi Boon Hui*

M2-Pyruvate Kinase in the detection of colorectal cancer [pg 18]

Goh Khean Lee

EVI2B, ATP2A2, S100B, TM4SF3, and OLFM4 As Potential Prognostic Markers for Postoperative Taiwanese Colorectal Cancer Patients [pg 18]

Wang Hwei-Ming

Colosentry<sup>®</sup>: A novel approach to decision-making and screening in colorectal cancer [pg 19]

Liew Choong Chin

Fit screening in Ibaraki Prefecture, Japan. An advantage of two-day sampling method [pg 20]

Yoko Saito

0830 – 1030

#### **SYMPOSIUM 2**

Kedah / Selangor Room

Allied Health Professional Session (1)

Stoma care: The way forward [pg 16]

Carol Stott

Empowering patients and facilitating changes: Experience in stoma care [pg 17]

Mariam Mohd Nasir

The development of stoma care in Indonesia – Past, present and future

Widasari Gitaraja

1030 – 1100

Tea

1100 - 1230

#### **SYMPOSIUM 4**

Kedah / Selangor Room

Allied Health Professional Session (2)

Nursing management of patient undergoing ostomy surgery [pg 21]

Wong Jing Yin

Difficult siting: How we do it?

Rozita Mohamad

The role of the World Council of Enterostomal Therapist (WCET) in educating nurses in stomacare [pg 21]

Carol Stott

Paediatric stoma [pg 22]

Norsiah Ishak

How effective is convexity? [pg 22]

Tai Seow Beng





## DAILY PROGRAMME

### 7<sup>th</sup> March 2014, Friday

1215 - 1300

**LUNCH SATELLITE SYMPOSIUM** (Johnson & Johnson)

Sabah Room

*Chairperson: Wan Khamizar Wan Khazim*

Avoiding complications in laparoscopic colon and rectal surgery

Lee Kil Yeon

1300 - 1415

Lunch

Sarawak Room

Friday Prayers

1415 - 1500

**PLENARY 2**

Sabah Room

*Chairperson: Ismail Sagap*

Optimising outcomes in colorectal cancer surgery

Law Wai Lun

1500 - 1630

**SYMPOSIUM 5**

Sabah Room

Colorectal and Anorectal Conditions

*Chairpersons: M Sarkunna Thas / Ballan Kannan*

Rectovaginal fistula – Choosing the right procedure

Charles Tsang

Enhanced recovery programme for colorectal surgery [pg 23]

Varut Lohsiriwat

Perianal Crohn's disease - A multidisciplinary approach [pg 23]

Alessandro Fichera

Functional outcome after low anterior resection

Ronan Cahill

1630 - 1800

How I Do It (incorporating Tea)

Sabah Room

*Moderators: Mohamad Ismail Ali / Gerald Fitzgerald Henry*

- Single port total colectomy for medically refractory colitis

Ronan Cahill

- Laser treatment in proctology [pg 24]

Thomas Deska

- APR

Wan Khamizar Wan Khazim

- Transanal Endoscopic Microsurgery (TEM): Technique and long-term outcomes [pg 25]

Eiji Kanehira

1400 - 1700

Allied Health Professional Session Kedah / Selangor Room

**Presentations by Companies and Workshop**

1400 - 1530

- Convatec

1530 - 1700

- Alcare

1800 - 1900

**MSCRS AGM**

Perak Room

1930 - 2200

GALA Dinner

Sarawak Room



## DAILY PROGRAMME

### 8<sup>th</sup> March 2014, Saturday

0830 – 1000

#### **SYMPOSIUM 6**

Sabah Room

Management of Intra-Abdominal Sepsis

*Chairpersons: Ong Kee Thiam /  
Tee Shin San*

Anastomotic leaks: Early diagnosis and management [pg 25]

Alessandro Fichera

Perforated diverticulitis

Law Wai Lun

Perforated colorectal cancers

John R Monson

Antibiotic usage in colorectal sepsis [pg 26]

Adrian Brink

1000 – 1045

#### **PLENARY 3**

Sabah Room

*Chairperson: Samuel Tay*

Haemorrhoids – From basic research to clinical practice [pg 28]

Varut Lohsiriwat

0830 – 1030

#### **SYMPOSIUM 7**

Kedah / Selangor Room

Allied Health Professional Session (3)

*Moderator: Mohd Rahime Ab Wahab*

Forum: Real life experiences of an ostomate [pg 26]

Sri Tharan

Yuliana Trihartati

Zainuddin Tahir

Nor Azizah Ismail

Regulating bowel movement – Can colostomy irrigation help? [pg 27]

Video presentation on Colostomy Irrigation

Tai Seow Beng

Case study: Stoma prolapse

Vickneswary Mayandy

Case study: Management of ileal conduit [pg 27]

Mohamad Amirudin Jaafar

Care of stoma patient undergoing radiotherapy / chemotherapy

Rozita Mohamad

0900 – 1030

#### **SYMPOSIUM 8**

Perak Room

Colorectal Cancer Survivorship Session (1)

#### **Panel Discussion**

*Moderators: Ranjit Kaur /  
Shamsuddin Bardan*

Health insurance issues for cancer patients / survivors

Mohamad Manmohan Abdullah

Cancer and employment: Implications for survivors and employers

Chow Sze Loon

The economic burden of cancer care: Medical care and family costs

Lim Teck Onn

Q & A

Tea



## DAILY PROGRAMME

### 8<sup>th</sup> March 2014, Saturday

1115 – 1300

#### SYMPOSIUM 9

Sabah Room

Rectal Cancer

*Chairpersons: Lim Teik Mau /  
Manohar Padmanathan*

Lymphatic mapping for rectal cancer

Ronan Cahill

Neoadjuvant therapy for rectal cancer -  
Who should get chemoradiation? [pg 28]

April Camilla Roslani

Approaching zero APR for lower rectal  
cancer

John R Monson

Management of obstructed rectal  
cancer

Law Wun Lun

1100 – 1230

#### SYMPOSIUM 10

Kedah / Selangor Room

Allied Health Professional  
Session (4)

Continent urinary diversion and  
neobladder [pg 29]

Carol Stott

Malaysian enterostomal therapy nursing  
education programme: Challenges and  
opportunities [pg 29]

Mariam Mohd Nasir

Sharing experiences as a newly qualified  
Enterostomal Therapist (E.T.)

*Moderator: Rozita Mohamad*

1. Malaysian ETNEP 2010,  
Penang  
Azniwani Yusoff
2. Malaysian ETNEP 2013  
UMMC, Kuala Lumpur [pg 30]  
Noorfariza Hussin
3. Malaysian ETNEP 2013  
UMMC, Kuala Lumpur [pg 30]  
Azizan Mohd Isa
4. Malaysian ETNEP 2013  
UMMC, Kuala Lumpur  
Tan May Nie

1100 – 1300

#### SYMPOSIUM 11

Perak Room

Colorectal Cancer Survivorship  
Session (2)

*Chairpersons: Sri Tharan / Cynthia Chu*

Navigating survivorship – Management  
of psychosocial issues

Bharathi Vengadasalam

Role of CORUM in supporting patients  
and the way forward

Ranjit Kaur

Surgery for colorectal cancer – What  
you need to know

Meheshinder Singh

Simple tricks in home management of  
stoma

Mariam Mohd Nasir

Q & A

1300 – 1415

#### LUNCH SATELLITE SYMPOSIUM (Sanofi-Aventis)

Sabah Room

*Chairperson: Akhtar Qureshi*

Adhesion prevention in colorectal surgery

John R Monson

Lunch

Sarawak Room



## DAILY PROGRAMME

### 8<sup>th</sup> March 2014, Saturday

1415 - 1500

#### **PLENARY 4**

Sabah Room

*Chairperson: Meheshinder Singh*

Antibiotic stewardship programme:  
Improving outcomes in an era of  
multidrug resistance [pg 31]

Adrian Brink

1500 - 1600

#### **PANEL DISCUSSION**

Sabah Room

Minimally Invasive Surgery

*Moderators: Yunus Gul / Paul Selvindoss*

Standard laparoscopy – Is there a need  
for a better technique?

Ronan Cahill

Hand-assisted laparoscopic surgery –  
Is there still a role?

Paul Selvindoss

NOTES – Is it a worthy effort? [pg 31]

Alessandro Fichera

Robotic Surgery – Is it a worthwhile  
investment?

Law Wai Lun

Development of a multi-channel port  
(x-Gate®), BJ needle®, and DraCo® to  
facilitate safe reduced port surgery:  
How to revive “The lost triangle” [pg 32]

Eiji Kanehira

1600 - 1730

#### **PROFESSORS' CORNER**

Sabah Room

(incorporating Tea)

Case Discussion - Use and  
Limitations of PET Scan in  
Colorectal Surgery

*Moderators: Lu Ping Yan /  
Chong Hoong Yin*

*Panel:*

Lee Boon Nang (Malaysia) –  
Nuclear Medicine Specialist

Abdul Samad Sakijan (Malaysia) – Radiologist

Fuad Ismail (Malaysia) – Oncologist

John R Monson (USA) – Surgeon

Samuel Tay (Malaysia) – Surgeon

Yunus Gul (Malaysia) – Surgeon

1400 - 1700

Kedah / Selangor Room

#### **Presentations by Companies and Workshop**

1400 – 1530

- Coloplast

1530 – 1700

- B Braun

1430 - 1630

Perak Room

#### **ROUND TABLE DISCUSSION**

Colorectal Cancer Survivorship

1630 - 1645

Tea

1645 - 1800

#### **CORUM AGM**

Perak Room



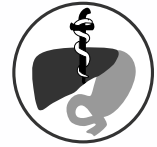9<sup>th</sup> March 2014, Sunday

## POSTGRADUATE ROUND

Time : 0900 – 1200 hrs Faculty : Ronan Cahill  
Venue : Universiti Kebangsaan Malaysia, Kuala Lumpur Convenor : Ismail Sagap

## POST-CONGRESS WORKSHOP

### 'BRIDGING THE GAP' – MULTIDISCIPLINARY MANAGEMENT OF INFLAMMATORY BOWEL DISEASE (organised in collaboration with the Malaysian Society of Gastroenterology and Hepatology)



Time : 0800 – 1300 hrs  
Venue : Perak & Selangor, Shangri-La Hotel, Kuala Lumpur  
Convenor : April Camilla Roslani  
Organising Committee : Raja Affendi Raja Ali / Ida Normiha Hilmi  
Invited Faculty : Alessandro Fichera / Shanthi Palaniappan / Nik Raihan Nik Mustapha / Petrick Periyasamy

#### Programme

- 0800 - 0805** Welcoming Address  
[April Camilla Roslani](#)
- 0805 - 0820** Overview of IBD in Malaysia  
[Ida Normiha Hilmi](#)
- 0820 - 0835** Multi-Disciplinary Management – *To MDT or not to MDT?* [pg 33]  
[Alessandro Fichera](#)
- 0835 - 0850** The Role of Endoscopy in IBD:  
Diagnosis, Severity Assessment and Dysplasia Surveillance  
[Shanthi Palaniappan](#)
- 0850 - 0905** Endoscopic Techniques for IBD Management  
[Ida Normiha Hilmi](#)
- 0905 - 1015** Case Presentations:  
Challenges in Diagnosing IBD  
[Nik Raihan Nik Mustapha / Petrick Periyasamy](#)  
Cases presented will illustrate:
- Why Results are Inconclusive
  - What Surgeons and Gastroenterologists can do to Help Optimize Samples
- 1015 - 1030** Coffee
- 1030 - 1145** IBD Surgery: Minefield or Solution? [pg 33]  
[Alessandro Fichera](#)  
Cases presented will include utilization of:
- Minimally Invasive Surgery for IBD
  - Bowel Sparing Surgery for Crohn's Disease
  - Biologics in Peri-Operative Management of CD
- Panel Discussion:**  
*Moderators: April Camilla Roslani / Raja Affendi Raja Ali*
- 1145 - 1300** Management of Difficult to Treat IBD Conditions
- Management of Acute Fulminant Colitis
  - Management of Pouchitis
  - Fistulizing Crohn's Disease – Management Strategies
- 1300** Lunch

\*Please note that each topic will be based on short lectures and/or case presentations and panel discussions incorporating interactive audience voting.





## CONFERENCE INFORMATION

### CONGRESS VENUE

#### **Shangri-La Hotel Kuala Lumpur**

11 Jalan Sultan Ismail, 50250 Kuala Lumpur, Malaysia

Tel: (603) 2026 8488

Fax: (603) 2032 1245

### REGISTRATION

The registration hours are:

6 <sup>th</sup> March 2013 (Thursday)	1600 to 1900 hrs
7 <sup>th</sup> March 2013 (Friday)	0730 to 1800 hrs
8 <sup>th</sup> March 2013 (Saturday)	0730 to 1800 hrs
9 <sup>th</sup> March 2013 (Sunday)	0730 to 1300 hrs

### IDENTITY BADGES

Delegates are kindly requested to wear identity badges during all sessions and functions.

### ENTITLEMENTS

Registered delegates will be entitled to the following:

- Admission to the scientific sessions, satellite symposia and trade exhibition
- Conference bag and materials
- Gala Dinner
- Lunches & Coffee/Tea

### SPEAKERS AND PRESENTERS

All speakers and presenters are requested to check into the Speaker Ready Room at least two hours prior to their presentation. There will be helpers on duty to assist with your requirements regarding your presentation. The Speaker Ready Room is located at the Sabah Ante Room, Shangri-La Hotel, and the operating hours are:

6 <sup>th</sup> March 2013 (Thursday)	1600 to 1900 hrs
7 <sup>th</sup> March 2013 (Friday)	0730 to 1800 hrs
8 <sup>th</sup> March 2013 (Saturday)	0730 to 1800 hrs
9 <sup>th</sup> March 2013 (Sunday)	0730 to 1100 hrs

All presentations will be deleted from the conference computers after the presentation are over.

### POSTERS

Posters will be displayed at Ballroom Foyer. The Organising Committee bears no responsibility for the safekeeping of posters. Any posters not collected by the close of the poster session will be discarded.

### PHOTOGRAPHY & VIDEOTAPING POLICIES

No photography or videotaping of the presentations is permitted during the scientific sessions.

### MOBILE PHONE

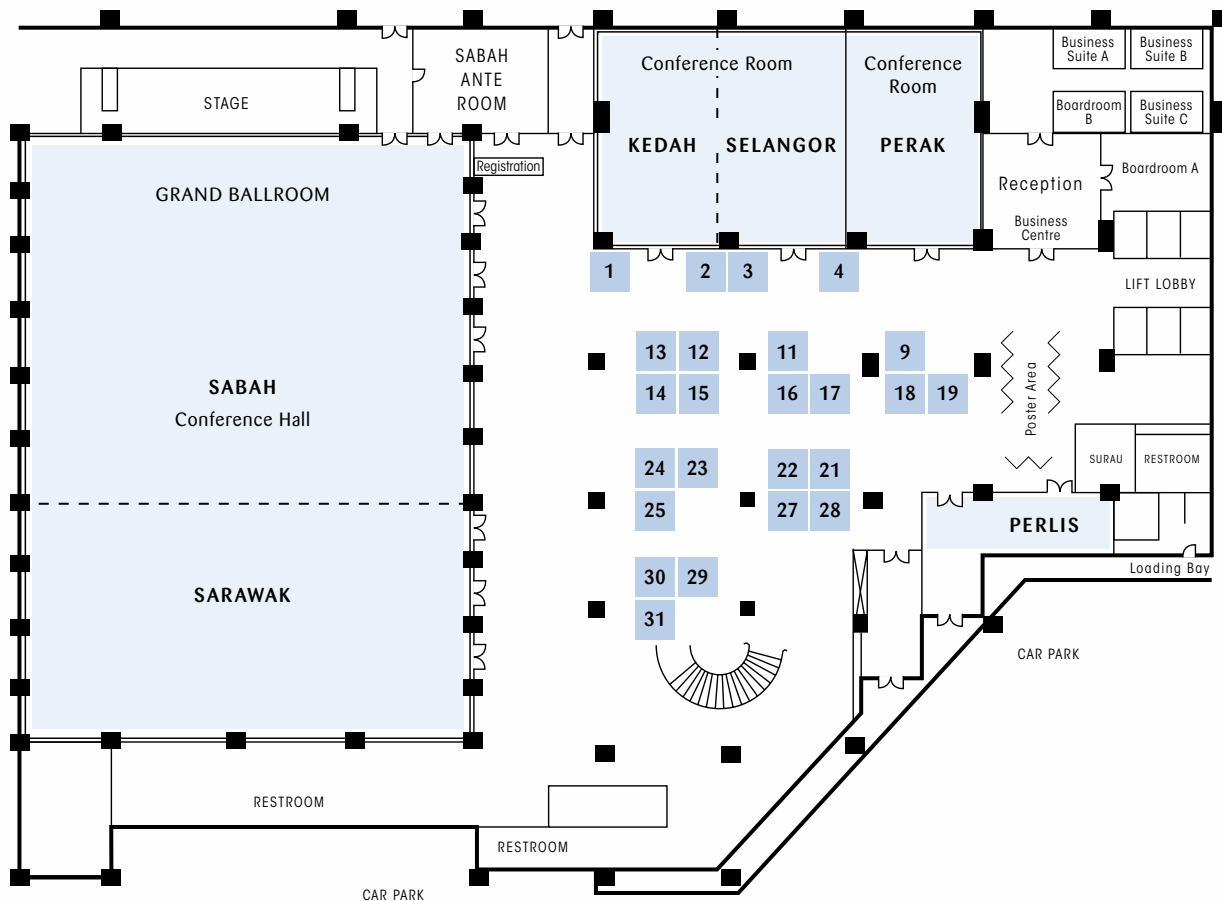
For the convenience of all delegates, please ensure that your mobile phone is silenced during the conference sessions.

#### **DISCLAIMER**

Whilst every attempt would be made to ensure that all aspects of the Convention as mentioned in this publication will take place as scheduled, the Organising Committee reserves the right to make last minute changes should the need arises.



## FUNCTION ROOMS & TRADE EXHIBITION



BOOTH NO	COMPANY	BOOTH NO	COMPANY
1	Alere Health Sdn Bhd	17	Servier Malaysia Sdn Bhd
2	UMMI Surgical (Karl Storz)	18	AstraZeneca Sdn Bhd
3	Medi-Life (M) Sdn Bhd	19	Medic Pro Supplies Sdn Bhd
4	Endodynamics (M) Sdn Bhd	21	BH Enterprise Sdn Bhd
9	MKS Medic Sdn Bhd	22	B Braun Medical Supplies Sdn Bhd
11	Fresenius Kabi Malaysia Sdn Bhd	23	Avro Medical Sdn Bhd
12	Convatec Malaysia Sdn Bhd	24 & 25	Johnson & Johnson Medical Malaysia
13 & 14	Covidien / Tyco Healthcare Medical Supplies Sdn Bhd	27	Sanofi-Aventis (Malaysia) Sdn Bhd
15	Qvanstar Biotech Sdn Bhd	28	United Italian Trading (M) Sdn Bhd
16	Biolitec (M) Sdn Bhd	29	Malaysian Healthcare Sdn Bhd
		30 & 31	Takeda Malaysia Sdn Bhd



## ACKNOWLEDGEMENTS

The Organising Committee of the Coloproctology 2014 wishes to thank the following for their support and contribution:

### MAJOR SPONSORS

Covidien / Tyco Healthcare Medical Supplies Sdn Bhd  
Johnson & Johnson Medical Malaysia

### SPONSORS

Takeda Malaysia Sdn Bhd  
Abbvie Sdn Bhd  
Alere Health Sdn Bhd  
AstraZeneca Sdn Bhd  
Avro Medical Sdn Bhd  
B Braun Medical Supplies Sdn Bhd  
BH Enterprise Sdn Bhd  
Biolitec (M) Sdn Bhd  
Convatec Malaysia Sdn Bhd  
Endodynamics (M) Sdn Bhd  
Fresenius Kabi Malaysia Sdn Bhd  
Malaysian Healthcare Sdn Bhd  
Medic Pro Supplies Sdn Bhd  
Medi-Life (M) Sdn Bhd  
MKS Medic Sdn Bhd  
Quanstar Biotech Sdn Bhd  
Sanofi-Aventis (Malaysia) Sdn Bhd  
Servier Malaysia Sdn Bhd  
United Italian Trading (M) Sdn Bhd  
UMMI Surgical (Karl Storz)  
Infors



**SYMPOSIUM 1**  
**Complex Fistula**

**ANATOMY OF FISTULA-IN-ANO**

Arun Rojanasakul

Division of Colorectal Surgery, Department of Surgery, King Chulalongkorn Memorial Hospital, Rama IV Patumwan, Bangkok, Thailand

Anatomy of the anal canal especially anal sphincters and anal spaces are very important to the understanding and management of fistula in ano. Unfortunately, details of the anatomy of this area are difficult to define, and many controversies are still abounded. Regarding anal sphincters, our studies in soft cadavers show that the external sphincter complex is composed of three separated muscles, which are (1) inseparable levator ani (the muscle cannot separate to be puborectalis, pubococcygeus, and ileococcygeus) (2) superficial external sphincter (3) subcutaneous external sphincter. The longitudinal muscle, which continue from the upper part of the rectum can be seen adhere along the entire length of the internal sphincter. At the levator muscle level, the superior fascia of the levator ani adheres, not combine, to the longitudinal muscle. The longitudinal fascia seems to appear at the level of superficial external sphincter, passes outward, separates levator ani and superficial external sphincter and also separates superficial external sphincter from subcutaneous external sphincter. Finally, the fibers traverse the subcutaneous external sphincter, separate the muscle into many small bundles. In our opinion, the concept of conjoined longitudinal muscle needs to be revised.

There are many spaces and potential spaces around the anus, which are intersphincteric space, perianal space, superficial post anal space, deep post anal space, ischioanal space, and supralelevator space. Current description of deep post anal space in the literature is not correct, in fact, deep post anal space is the intramuscular space between posterior triangular extension of superficial external sphincter and levator ani, this space is not the isthmus of posterior ischioanal spaces as described by Courtney. The cryptoglandular abscess begin with infection of intramuscular gland, and become the intersphincteric abscess. The intersphincteric abscess spread to other spaces along longitudinal fascia, and not break through anal sphincters. The abscess in the deep post anal space can spread to one or both sides of the ischioanal space to be semi-horseshoe or complete-horseshoe abscess respectively. The supralelevator abscess is the higher extension of intersphincteric abscess, not the upward extension from the ischioanal abscess through the levator ani muscle, as described in the literature.

Since the abscess spread between the separated muscles, not pass through the muscles, then the fistula ramification should have fixed constant patterns which are intersphincteric type (the fistula tract pass between internal sphincter and subcutaneous external sphincter), low transphincteric type (the fistula tract lie below the superficial external sphincter), the high transphincteric type (the fistula tract lie between the superficial external sphincter and levator ani muscle). The high transphincteric fistula in the posterior direction almost always enter the deep post anal space and spread to ischioanal space(s). The high transphincteric fistula in the anterior direction are always the straight tract, extend from the anus to the urogenital area. The suprasphincteric and extrasphincteric fistula may not occur in nature but are iatrogenic. From the above patterns of fistula in ano, we suggest that the available classification of fistula in ano should be reconsidered.



**SYMPOSIUM 1**  
**Complex Fistula**

**MANAGEMENT OF COMPLEX FISTULA-IN-ANO**

Arun Rojanasakul

Division of Colorectal Surgery, Department of Surgery, King Chulalongkorn Memorial Hospital, Rama IV Patumwan, Bangkok, Thailand

Complex fistula in ano was defined by the American Society of Colon and Rectal Surgeons (2011 version) as: High transphincteric fistula (pass above 30% of external sphincter), Suprasphincteric fistula, Extrasphincteric fistula, Horseshoe fistula, fistula from other causes (inflammatory bowel disease, radiation, malignancy, pre-existing incontinence, chronic diarrhea) and anterior fistula in women.

The recommended treatments are: fibrin glue(2C), fibrin plug(2C), endoanal advancement flap(1C), Seton with staged fistulotomy(1B), LIFT.

In my opinion, the accepted concepts of fistula in ano are controversy. Many complex fistula such as suprasphincteric and extrasphincteric fistula are extremely rare and may not occur in nature, and inexperienced surgeons always create them. Regarding the management of complex fistula in ano, LIFT is my preferred procedure. The drawback of LIFT is technical demanding in some situations and the reported worldwide outcome were variable (60-90% success).

At present, some innovative or improving techniques are still required. We currently proposed external sphincter preserved fistulotomy which is an easier technique and the early outcome is quite impressive.

**SYMPOSIUM 2**  
**Allied Health Professional Session (1)**

**STOMA CARE: THE WAY FORWARD**

Carol Stott

Stomal Therapy & Wound Care CNC, Prince of Wales Hospital, Randwick, New South Wales, Australia

Enterostomal therapy nursing (ETN), encompasses stoma care, wound management and the promotion of urinary and faecal continence. Many factors can impact on ETN including changing patient requirements and financial and professional considerations.

The evolution and continuance of ETN in Malaysia will be the focus of this presentation. Education (beginning and continuing), clinical practice and professional development will all be canvassed.

Communication and education is now possible online. This has opened up many possibilities for ETN. This includes online distance education courses, 'telehealth' and videoconferencing. All of these strategies have been found to be useful supports for clinical practice in stoma, wound and continence management. Thanks to the internet, education delivery can now be straightforwardly initiated from the other side of the world.. Distance education is now coming of age as interactive discussions in 'real time' are now possible, due to continuing improvements in information technology (IT).

In most western countries, cost is a fundamental factor to be considered in any clinical development strategy. In recent years, initiatives that support early discharge from hospital have been increasingly prized and preventative health strategies continue to be prioritised, explored and developed. In this light, this presentation will canvass the increasing potential for nurse-led clinics in ETN, and the widening role for community based ETNs.

Malaysia like Australia, has rural and remote areas that do not have comparable access to health care as their metropolitan counterparts. New IT resourced initiatives such as 'telehealth' have great potential in this context. ETN is a small and discrete nursing specialty and good educational initiatives that are available and cost-effective need to be encouraged. This applies to both educational preparation in ETN and continuing professional development as we continue to pursue our goal of keeping abreast of new clinical innovations as they occur.





**SYMPOSIUM 2**  
Allied Health Professional Session (1)

## **EMPOWERING PATIENTS AND FACILITATING CHANGES: EXPERIENCE IN STOMA CARE**

Mariam Mohd Nasir

Nursing Officer/Enterostomal Therapist (ET), Department of Nursing, Universiti Malaya Medical Centre, Kuala Lumpur, Malaysia

As the healthcare advanced, healthcare providers have greater roles and responsibilities especially in a specialized care, including stoma care. We know that stoma care is a self care, where by patient need to take care of the stoma themselves especially if it is a permanent stoma with or without the help of their significant others.

How can we care for them all the times since we will not able to be at the patient side 24 hours around the clock? Educating the patients and giving them empowerment to care for their stoma is the best solution, thus helping the patient in their adaptation process including rehabilitation. We need to move forward and change the way we manage the patient and we have to look at it positively and make the patient understand this is for their own good.

Empowerment is based on the idea that giving the patient and their family members skills, resources, authority, opportunity, motivation, as well holding them responsible and accountable for outcomes of their actions, will contribute to their competence and satisfaction.

We as the providers will continuously stand by their side to offer help and support whenever they needs it and provide an option for any problems that they are facing

The speaker will share with all how the health care provider can help facilitate the changes without making the patients feel the care as something burdening them. The speaker will also highlight the advantages of it and impact on the patient self care and how we going to do it?

### **PLENARY 1**

## **CHALLENGES IN IBD**

A Fichera

University of Washington Medical Center, Seattle, WA, USA

Current treatment of inflammatory bowel disease has significantly evolved over the last decade both in medicine and in surgery. With introduction more effective medical therapy, we have improved response rates, but we have also selected a subgroup of patients that do not respond to medical therapy and present to surgery severely malnourished, immunocompromised and more prone to postoperative complications.

During this presentation:

- 1) We will review the indication and timing of surgical intervention in IBD patients.
- 2) We will discuss the challenges that the surgeons had to face when treating IBD patients that have failed medical therapy.
- 3) We will look at the surgical strategies to decrease postoperative complications, preserve intestinal length, improve quality of life and decreased the risk of postoperative recurrence.



**SYMPOSIUM 3**

Recent Advances in Detection of Colorectal Cancers

**M2-PYRUVATE KINASE IN THE DETECTION OF COLORECTAL CANCER**

K L Goh

Professor of Medicine, Head of Gastroenterology and Hepatology, University of Malaya, Kuala Lumpur, Malaysia

The M2 isoenzyme of pyruvate kinase (M2PK) is a key enzyme in glycolysis and catalyzes the conversion of phosphoenolpyruvate to pyruvate with the production of ATP and energy. This is a highly efficient metabolic process. In tumor cells, the normal tetrameric form of M2PK, on exposure to oncoproteins is converted to an inactive dimeric form. Phosphometabolites above pyruvate kinase (e.g. glycerate 3-P and fructose 1, 6-P2) accumulate and are available as precursors for synthetic processes such as nucleic acid, phospholipid and amino acid synthesis. These substrates are needed for tumorigenesis. The dimeric M2PK enzyme is often called "Tumor" M2 PK and in colorectal cancers (CRC) this protein is shed/secreted by the tumor and passed out with stools. This forms the basis of detection of CRC using the stool M2PK test which is made by Schebo Biotech AG, Germany.

We undertook a prospective case-control study to validate the M2PK Stool Quick Test in the detection of CRC. A total of 100 consecutive cases of CRC were recruited from April 2012-May 2013 which were matched to 200 controls with normal colonoscopy. This test was performed according to manufacturer's instructions and was found to be highly accurate with a diagnostic accuracy of 96.0% with a sensitivity of 93.0% and a specificity of 97.5%.

Stool tests play an important role in the detection of CRC and is an integral part of many CRC screening programs. Guaiac-based stool occult blood tests have now been superseded by Fecal Immunochemical Tests. Fecal DNA test have been increasing tested and used in the US but have the drawback of high costs and is still being further refined. The M2 PK stool test offers a highly viable alternative to these tests especially with the convenience of an immediate, office (clinic) based test giving a very high diagnostic accuracy rate.

**SYMPOSIUM 3**

Recent Advances in Detection of Colorectal Cancers

**EVI2B, ATP2A2, S100B, TM4SF3, AND OLFM4 AS POTENTIAL PROGNOSTIC MARKERS FOR POSTOPERATIVE TAIWANESE COLORECTAL CANCER PATIENTS<sup>2</sup>**

Hwei-Ming Wang<sup>1</sup>, Ming-Yii Huang<sup>2</sup>

<sup>1</sup>Division of Colorectal Surgery, Department of Surgery, Taichung Veterans General Hospital, Taichung, Taiwan

<sup>2</sup>Department of Radiation Oncology, Cancer Center, Kaohsiung Medical University Hospital, Kaohsiung, Taiwan

Undetected micrometastasis may play a key role in the early relapse of colorectal cancer (CRC) patients. The aim of this study was to detect circulating tumor cells (CTCs) for predicting early relapse of CRC patients by a weighted enzymatic chip array (WEnCA) and analyze 15 candidate genes associated with CRC carcinogenesis.

The genes of 105 postoperative CRC patients were analyzed by membrane array and direct sequencing. We constructed a WEnCA platform including five prognosis-related genes and analyzed the detection rate of WEnCA for CTCs in 30 clinically confirmed CRC relapse patients. Postoperative relapse was significantly correlated with gene overexpression, including EVI2B (p = 0.001, OR= 4.622), ATP2A2 (p = 0.006, OR= 4.688), S100B (p = 0.001, OR= 11.521), TM4SF3 (p = 0.001, OR= 6.756), and OLFM4 (p = 0.008, OR= 3.545). Using WEnCA (weighting score of each gene: 5 to EVI2B, 5 to ATP2A2, 12 to S100B, 7 to TM4SF3, and 4 to OLFM4), we could detect CTCs presenting these genotypes in relapsed CRC patients. The sensitivity, specificity, and accuracy were 94.7%, 93.5%, and 97%, respectively. The results of the present study suggest that EVI2B, ATP2A2, S100B, TM4SF3, and OLFM4 could be potential prognostic markers for CRC patients.



**SYMPOSIUM 3**

Recent Advances in Detection of Colorectal Cancers

**COLONSENTRY®: A NOVEL APPROACH TO DECISION-MAKING AND  
SCREENING IN COLORECTAL CANCER**

Choong-Chin Liew

Founder and Chair, GeneNews (Malaysia) Sdn Bhd

Brigham and Women's Hospital, Harvard Medical School, Boston, Massachusetts, United States

Department of Laboratory Medicine and Pathobiology, University of Toronto, Toronto, Ontario, Canada

Colorectal cancer (CRC) is the second leading cause of cancer deaths in North America, and is fast emerging as a major gastrointestinal cancer in the Asia-Pacific region, including Malaysia. We have developed a blood-based risk stratification approach to pre-screen average-risk populations for colorectal cancer. This approach is expected to enhance compliance with screening colonoscopy, ultimately leading to earlier detection of colorectal cancer.

Our test for colorectal cancer is based in our novel gene expression profiling technology, *Sentinel Principle*®. The *Sentinel Principle* posits that since blood cells interact with all human tissues these cells serve as valuable “sentinels” that can reflect underlying states of health or disease. Our laboratory has confirmed the promising utility of this blood-based technology for disease prognostics and diagnostics across a range of different conditions. We have been able to generate from blood samples specific gene expression profiles sufficient to differentiate diseases as diverse as schizophrenia, bipolar disorder, various cardiovascular diseases, osteoarthritis, Crohn's disease, prostate cancer, nasopharyngeal cancer, liver cancer and bladder cancer.

We have also applied this research to develop biomarkers for colorectal cancer. Our test based in this research, *ColonSentry*®, is the world's first blood-based test for colorectal cancer. Information provided by this test can assist patients and physicians in colorectal screening decision-making. *ColonSentry* is now available in the United States, Canada, China and Malaysia.



**SYMPOSIUM 3**

Recent Advances in Detection of Colorectal Cancers

**FIT SCREENING IN IBARAKI PREFECTURE, JAPAN.  
AN ADVANTAGE OF TWO-DAY SAMPLING METHOD**

Y Saito<sup>1,2</sup>, H Suzuki<sup>3</sup>, I Hyodo<sup>2,3</sup>, I Yamaguchi<sup>4</sup>,

<sup>1</sup>Ibarakiken Medical Center, Mito, Japan

<sup>2</sup>Sub-committee for Colorectal Cancer, Ibaraki Prefectural Council for Controlling and Preventing Life Style-related Disease, Japan

<sup>3</sup>Department of Gastroenterology, University of Tsukuba, Tsukuba, Japan

<sup>4</sup>Ibaraki Health Association, Mito, Japan

**INTRODUCTION**

In Japan, a two-day sampling method through immunological fecal occult blood test (FIT) is widely accepted by colorectal cancer screening program according to Japanese Colorectal Cancer (CRC) screening guidelines.

**AIMS & METHODS**

The purpose of this study is to evaluate the positive predictive values and Dukes classification of identified colorectal cancer between the first day positive and the first day negative group. For Regional Screening Program from 2007 to 2011, FIT participants, who were over 40 years old, were screened with 2 samples of stool measured by the OC-SENSOR (Eiken, Japan) with a cut-off value of 100ng/mL (20µg Hb/g stool). The number of participants was 616,086. The participant gender was 41.2% male and 58.8% female. The FIT positive participants were classified into the first day positive group (++) (+-) (+) and negative group (-+).

**RESULTS**

The positive FIT participants was 44,445 in number, and the total FIT positive rate was 7.21%. The number of the first day positive and negative participants were 27,332(61.5%) and 17,113(38.5%) respectively. Work-up examination rates were 72.9% and 74.4% respectively. The number of two-day positive participants was 8,298(18.7%). CRCs were identified in 1,079 cases. Eight hundred and forty-six (846) cases were from the first day positive group and 233 cases were from the first day negative group. The positive predictive values between the first day positive and negative group were 3.095% and 1.362% respectively. The positive predictive value of FIT-positivity in both days was 6.773%. One thousand and seventy-nine (1,079) cases were classified according to Dukes classification. Those were 504 (Dukes A intra-mucosal carcinoma), 303(Dukes A invasive carcinoma), 122(Dukes B), 128(Dukes C), 17(Dukes D) and 5(unknown). Three hundred and sixty-five(335) cases of Dukes A intra-mucosal carcinoma, 242 cases of Dukes A invasive carcinoma, 111 cases of Dukes B, 108 cases of Dukes C, and 16 cases of Dukes D were from the first day positive group.

**CONCLUSION**

If one-day sampling of FIT were adopted in the screening program, 27.6% (139/504) of Dukes A intra-mucosal carcinoma and 20.1% (61/303) of Dukes A invasive one would be missed. The highest positive predictive value was shown in the FIT both days-positive group.



**SYMPOSIUM 4**  
Allied Health Professional Session (2)

**NURSING MANAGEMENT OF PATIENT UNDERGOING OSTOMY SURGERY**

Wong Jing Yin  
Malaysian ETNEP  
Enterostomal Therapist (ET), Pantai Hospital Ipoh, Ipoh, Perak, Malaysia

Nursing Management of patient undergoing ostomy surgery is a very crucial period for the patient and their family members. This will consist of pre operative and post operative period, where by the ET will inform in details about the surgery including physical and psychological preparation, educate them and also counseling.

E.T Nurses play important roles in assisting and helping patients undergoing ostomy surgery, in order to do that successfully, the E.T Nurses must have the knowledge, technical skills and able to provide emotional support for them.

Health education starts from the day patient agrees with the ostomy surgery until the patient is fit for discharge and return to the lifestyle they enjoyed before their surgery. Patients undergoing ostomy surgery benefit in terms of enhanced self-care, reduced anxiety, enhanced self-esteem, increased satisfaction in care and reduced disruption in daily functioning.

An effective nursing management will ensure patient have a quality of life after surgery. It will also help them in the process of adaptation and rehabilitation. The objective of this is to allow patient to enjoy their life to the fullest even with a stoma and lead their life as normal as possible.

**SYMPOSIUM 4**  
Allied Health Professional Session (2)

**THE ROLE OF THE WORLD COUNCIL OF ENTEROSTOMAL THERAPISTS (WCET) IN EDUCATING NURSES IN STOMA CARE**

Carol Stott  
Stomal Therapy & Wound Care CNC, Prince of Wales Hospital, Randwick, New South Wales, Australia

The mission statement of WCET is "to lead the global advancement of specialised professional nursing care for people with ostomy, wound or continence needs".

The WCET vision statement takes this further and says that specialised nursing care should be available to all people with ostomy wound and continence needs, and that speciality education for nurses in this field is provided so that they are able to fulfil this vision.

Most of the work of WCET therefore is about supporting and helping to educate nurses in Enterostomal therapy nursing (ETN). The International delegate (ID) position is pivotal to this as they are the people with local knowledge. This is imperative when looking at educational requirements in a country.

The work carried out by the education committee will be examined, especially looking at Enterostomal therapy nursing education programs (ETNEP's).

The Norma N Gill Foundation is the charitable arm of WCET and is concerned with scholarships which very importantly supports both individual nurses wanting to enrol in ETNEP's and also program support for new ETNEP's.

Continuing education and professional development for ETN's is crucial and is supported by the biannual WCET Congress and the WCET Journal.

This paper will relate how WCET fulfils the vision statement of educating nurses in ETN.





**SYMPOSIUM 4**  
Allied Health Professional Session (2)

**PAEDIATRIC STOMA**

Norsiah Ishak

Staff Nurse/Enterostomal Therapist(E.T.), SRN ETNEP(Mal), Sultanah Bahiyah Hospital, Alor Setar, Kedah, Malaysia

Incontinent stomas are surgically created openings that allow free flow of urine or faeces requiring a pouching system. Enterostomal Therapist has to face with many challenges in supporting and educating a child/parent/carer with any stoma. Their psychological, emotional and social issues will need to dependence on others.

As with adult patients, stomas are formed in children as a life-saving technique or to improve their quality of life. It is unsurprisingly a shattering experience for parents to be told that their baby or child requires a stoma (Webster, 1985), and the role of the paediatric stoma care nurse includes supporting the family and teaching the parents how to care for their child's stoma (Kean, 2002)

Maintaining pouching system can be also a big challenge to the E.T. especially immediate post-operative period where there is still pain and discomfort.

The principle of stoma care is the same as in adult and children but there are also some differences in term of the condition or indication and also the post-operative management special consideration such as the impact on emotional, social and growth. Other element is that majority stoma in children are temporary.

Normally the children will have last complications and in many situation it can be management well. The speaker will highlight the main challenges and appropriate management of paediatric stoma during the conference.

**SYMPOSIUM 4**  
Allied Health Professional Session (2)

**HOW EFFECTIVE IS CONVEXITY?**

Tai Seow Beng

SEGi College, Kuala Lumpur, Malaysia

Convex products are often recommended by ETs was considered when the stomal or abdominal topography was perceived of as compromising the seal between the pouch and peristomal skin. During application of convex product the outward curve of the adhesive skin barrier presses on the skin down around the stoma and pushes the stoma out giving a more secure seal and a better wear time.

According to literature review in Journal of WOCN 2013 revealed by Erwin Tooth, Doughty D convex product may be used to

(1) Prevent frequent leakage under the wafer caused by :-

- retracted stoma, flush stoma
- stoma tips down or at skin level
- wrinkles, creases in the skin
- Flaccid abdomen

(2) Improve wear time for patients and cost effective.

Convexity should be used with caution in the presence of peristomal varices, mucocutaneous separation, peristomal hernia, stomal prolapse. The used of convexity can caused pressure injury to peristomal skin.

**CONCLUSION**

Convexity has an essential role to play in the management of difficult stoma .When used appropriately it can provide patients with security and promote their physical and psychological wellbeing. The selection of suitable convexity usage should be monitored carefully following through assessment together with expert clinical judgement.



**SYMPOSIUM 5**  
Colorectal and Anorectal Conditions

**ENHANCED RECOVERY PROGRAMME FOR COLORECTAL SURGERY**

Varut Lohsiriwat

Division of Colon & Rectal Surgery, Department of Surgery, Faculty of Medicine Siriraj Hospital, Mahidol University, Bangkok, Thailand

Enhanced recovery after surgery (ERAS) is a multimodal programme of multidisciplinary care; aiming to minimise perioperative stress response, to support multiorgan function, and to help patients returning to normal physiological state sooner after surgery. ERAS has been initiated in the perioperative care pathway of colorectal surgery. Nowadays, this concept has been widely utilised in various operations. Focusing on coloproctology, there are three major phases in ERAS protocol: preoperative, intraoperative, and postoperative period. (1) Key ERAS elements in preoperative care include detailed preoperative assessment and counseling, optimal pre-existing comorbidities (if any), reassurance of adequate pain control, correction of malnutrition status, avoidance of prolonged fasting, selective application of mechanical bowel preparation, and attention to patient's concern (if any). (2) Key ERAS elements in intraoperative care include minimally invasive surgery whenever possible, preemptive analgesia and/or epidural analgesia, avoidance of hypothermia and fluid overload, judicious use of tube and drain, selective use of diverting stoma, and tension-free abdominal closure. (3) Key ERAS elements in postoperative care include early feeding and ambulation, prophylaxis of postoperative nausea and vomiting, and adequate pain control (preferential use of non-opioid drugs). Several recent meta-analyses and systematic reviews have confirmed that, compared to conventional care pathway, patients undergoing colorectal surgery with ERAS experienced shorter hospital stay, less postoperative complication, and quicker functional recovery. Undoubtedly, ERAS is a must care pathway for modern colorectal and anal surgery.

**SYMPOSIUM 5**  
Colorectal and Anorectal Conditions

**PERIANAL CROHN'S DISEASE – A MULTIDISCIPLINARY APPROACH**

A Fichera

University of Washington Medical Center, Seattle, WA, USA

Medical and surgical treatment of perianal Crohn's disease is extremely complex. Active perianal disease has a major impact on quality of life in this very young patient population. Aggressive surgical management may result in continence issues and permanent fecal diversion. On the other hand limited medical management may result in recurrent flares, progressive destruction of the sphincter complex also resulting in incontinence and suboptimal quality of life.

During this presentation:

- 1) We will review the current medical and surgical options for treatment of perianal Crohn's disease.
- 2) We will discuss the current data supporting a well-coordinated team approach between the surgeon and the gastroenterologists.
- 3) We will look at the surgical strategies to preserve sphincter function, optimize efficacy of medical management, improve quality of life and decrease the risk of postoperative recurrence.



## HOW I DO IT

# LASER TREATMENT IN PROCTOLOGY

Thomas Deska  
Marien-Hospital, Witten, Germany

### Laser Treatment in Proctology

- Laser Hemorrhoidoplasty (LHP)
- Fitula Laser Closure (FiLaC™)
- Laser Pilonidoplasty (LPP)

LHP – Best indications: large cushions with a light prolapsed, without large internal mucosal prolapsed. For Hemorrhoids Grade 3 – 4

- Almost Painless
- Office surgery possible
- No damage of anoderm
- Quick recovery

FiLaC – Best indications: Trans-sphincteric anal fistulas, multiple recurrences (Crohn's disease)

- No incontinence risk
- Destruction of the fistula track & additional collapsing
- Easy & time saving procedure – no excision
- Excellent healing rate up to 80%

LPP – Best indications: Chronic Phase without large abscess

- Quick & safe procedure with local anaesthesia in office setting
- Healing rate 75 – 90%
- Small wound with very fast convalescences
- Inability to work 2 – 7 days
- In case of recurrence repeat procedure again



**HOW I DO IT**

**TRANSANAL ENDOSCOPIC MICROSURGERY (TEM):  
TECHNIQUE AND LONG-TERM OUTCOMES**

Eiji Kanehira<sup>1</sup>, Takashi Tanida<sup>1</sup>, Aya Kamei<sup>1</sup>, Masafumi Nakagi<sup>1</sup>, Shoji Tsuchiya<sup>2</sup>, Amane Hideshima<sup>1</sup>

<sup>1</sup>Department of Surgery, Medical Topia Soka, Japan

<sup>2</sup>Department of Gastroenterology, Ageo Central General Hospital, Japan

**BACKGROUND**

The first author performed transanal endoscopic surgery (TEM) in 302 patients in Japan for the last 20 years, of which 153 were early rectal cancer cases. The short- and long-term outcomes of the early rectal cancer cases were herein reported.

**METHODS**

The original technique of TEM developed by Buess was performed in all cases. The hospital records were reviewed to assess the clinical outcomes. Questionnaire was sent to the patients to analyze the long-term outcomes.

**RESULTS**

153 early cancer cases included 115 T0 and 38 T1 lesions. Full-thickness resection was performed in 36 patients, while 117 underwent submucosal dissection. Conversion to laparoscopic low anterior resection occurred in one case. Mortality was nil. Major operative complication was noted in only one patient, who developed stenosis. 7 patients underwent immediate salvage surgery. 6 patients died of recurrence of rectal cancer. Disease-free survival rate at year 5 was 93.7%.

**CONCLUSIONS**

Our study, one of the largest series in the world, confirms that TEM is a preferable option in the surgical treatments of T0 and T1a rectal carcinoma. As far as early cancer cases are treated, submucosal resection seems to be sufficient. When risk of recurrence is found by pathological examination, immediate salvage operation is mandatory to improve the prognosis.

**SYMPOSIUM 6**

**Management of Intra-Abdominal Sepsis**

**ANASTOMOTIC LEAKS: EARLY DIAGNOSIS AND MANAGEMENT**

A Fichera

University of Washington Medical Center, Seattle, WA, USA

Anastomotic leak rates vary significantly between proximal and distal anastomosis, especially in the era of neoadjuvant combined modality therapy for locally advanced rectal cancer. More recently the role of mechanical bowel preparation with or without perioperative antibiotics and its role in postoperative septic complications including anastomotic leaks has been extensively debated. While we will not completely eliminate anastomotic leaks, it is critical to limit clinical severity, diagnose them early and properly intervene.

During this presentation:

- 1) We will review the current data on anastomotic leaks in non-emergent colorectal surgery
- 2) We will discuss the need for mechanical bowel preparation with and without any operative antibiotics and its role in anastomotic leaks.
- 3) We will look at the diagnostic modalities, interventions and preventive measures to decrease the rates of this devastating complication in our practices.



**SYMPOSIUM 6**  
Management of Intra-Abdominal Sepsis

**ANTIBIOTIC USAGE IN COLORECTAL SEPSIS**

Adrian Brink

Department of Clinical Microbiology, Ampath National Laboratory Services, Milpark hospital, Parktown, Johannesburg, South Africa

The incidence of peritonitis following colorectal surgery varies between 1% and 10% whilst the mortality associated with post-operative peritonitis ranges from 8% to 10% and depends upon operative site. Hence, principles of therapeutic management include procedure (s) that controls the source of infection and appropriate antibiotic treatment.

Important principles of antibiotic therapy per se include the fact that antibiotics should be initiated as soon as the diagnosis is established and surgery planned and from a PK/PD point of view, parenteral administration. Furthermore, antibiotics chosen must usually target Enterobacteriaceae and anaerobes directly responsible for the immediate prognosis (development of residual abscesses). Considerations in determining appropriate therapy are therefore based on site of perforation, dose and dosing frequency (PK/PD), prior antibiotic treatment, severity of illness, potential for engendering antibiotic resistance and nosocomial vs community onset and subsequently, prevalent pathogens [e.g. extended spectrum beta-lactamase (ESBL) producing Enterobacteriaceae vs *Pseudomonas aeruginosa*). In this regard, risk factors for multidrug-resistant (MDR) pathogens include hospitalization, immune suppression, postoperative infection, recent antibiotic therapy and old age/residence in long term-care facilities.

Little guidance in literature exists as to which agent is superior as studies are designed to test equivalence and patients in studies have not had severe community-acquired infections. If risk factors for MDR are not present, narrow spectrum empiric cover such as amoxicillin-clavulanate would suffice. Otherwise, ertapenem or tigecycline have appropriate spectrum that not only includes ESBLs but anaerobes as well particularly in the case of tigecycline. Hospital-acquired (HA) peritonitis (e.g due to anastomotic failure) possibly has a worse prognosis and whilst enterococci are more frequently cultured, the deleterious role in outcome is controversial. *P.aeruginosa* requires broader spectrum therapy such as piperacillin-tazobactam, meropenem, imipenem or doripenem and yeasts increase mortality in HA peritonitis. However, whether and when to empirically treat enterococci or candida remains controversial.

**SYMPOSIUM 7**  
Allied Health Professional Session (3)

**FORUM: REAL LIFE EXPERIENCES OF AN OSTOMATES**

Moderator:

Mohd Rahime Ab Wahab

Infection Control Department, University Malaya Medical Centre, Kuala Lumpur, Malaysia

Panel:

Sri Tharan, President, MOsA

Yuliana Trihartati (Indonesia)

Haji Zainuddin Tahir, Past President, MOsA

Norazizah Ismail, Assistant Secretary, MOsA

The invited panel members are an ostomate themselves and they will share their life story after ostomy surgery and the impact of having stoma to their daily life, family life, daily activities and some tips on the management.

They will also provide us with information how best we as Enterostomal Therapist (E.T.) or Nurses can assist the ostomate in the care especially the new ostomate, including the challenges, adjustment and adaptation.





**SYMPOSIUM 7**

Allied Health Professional Session (3)

**REGULATING BOWEL MOVEMENT- CAN COLOSTOMY IRRIGATION HELP?**

Tai Seow Beng

SEGi College, Kuala Lumpur, Malaysia

Colostomy irrigation a mechanical method to stimulate peristalsis, thus restore patient continence control over elimination, allows freedom of not wearing a bag instead a mini cap. Irrigation works on principle that if you evacuate all or most of the large bowel, it take 24 to 48 hours to start to make its way out of stoma again. This transit time will vary on what you eat and upon your particular metabolism.

There are advantages to irrigating including good continence control, lessen impact of altered body image, cost effective , more confidence to participate day to day activities such as sport, work, social activities and effects of faecal odour ,flatus, skin soreness are reduced.

The individual must have a sigmoid or descending colostomy, a reasonable amount of hand/eye coordination, capacity to learn and time devote to procedure. Irrigation is carried out regular time slot once a day or every other day .It takes 6 to 8 weeks for bowel to become regulated. An irrigation session takes about an hour.

Contraindications are hernia, ongoing bowel disease, serious heart or kidney disease and temporary or transverse colostomy.

**CONCLUSION**

This procedure have been dropped off over years, possibility due to improvement in appliance design, due to misconception hold by medical personnel and information on the subject was not well disseminated. This is an alternative method for those patients unable to afford to buy appliances but required to live QOL.

Steps of the procedure will be shown on video.

**SYMPOSIUM 7**

Allied Health Professional Session (3)

**MANAGEMENT OF ILEAL CONDUIT**

Mohamad Amirudin Bin Jaafar

Enterostomal Therapist (ET) Nurse, Urology Ward, University Malaya Medical Centre, Kuala Lumpur, Malaysia

An ileal conduit is a surgical techniques for the diversion of urine after a patient's bladder are removed due to its low complication rate and high patient satisfaction level. It is usually used in conjunction with radical cystectomy in order to control invasive bladder cancer. To create an ileal conduit, the ureters are surgically resected from the bladder and a ureteroenteric anastomosis is made in order to drain the urine into a detached section of ileum. The end of the ileum is then brought out through an opening (a stoma) in the abdominal wall. The urine is collected through a bag that attaches on the outside of the body over the stoma. While patient is still in the hospital, the Enterostomal Therapy(ET) Nurse or ward nurse will teach patient for manage their ileal conduit. Correct application of urostomy bag is important as it provides with a protective seal for the skin around patient's stoma to prevent irritated by the urine. It is anticipated that patient will feel confident in managing the bags before patient discharge. Case study was done for one of the patient in University Malaya Medical Centre(UMMC). The doctor was diagnosed him with advanced bladder cancer and decided to do a surgery after specific investigation done. ET Nurse was monitored his progress from pre until post operation. Health teaching is very important for patient especially post operation care. Management of stoma is very crucial as to prevent any complications. Improper management can cause urinary infection and peristomal skin excoriation. Therefore patient education and ability to manage the stoma and pouch application is very important. Professional support is essential.



**PLENARY 3**

**HAEMORRHOIDS: FROM BASIC RESEARCH TO CLINICAL PRACTICE**

Varut Lohsiriwat

Division of Colon & Rectal Surgery, Department of Surgery, Faculty of Medicine Siriraj Hospital, Mahidol University, Bangkok, Thailand

Haemorrhoids is a very common anorectal condition defined as the symptomatic enlargement and distal displacement of normal anal cushions. The abnormal dilatation and distortion of the vascular channel, together with destructive changes in the supporting connective tissue within the anal cushion, is a paramount finding of haemorrhoidal disease. There is emerging evidence that the dysregulation of the vascular tone and vascular hyperplasia might play an important role in haemorrhoidal development and could be a potential target for medical treatment. In most instances, haemorrhoids are treated conservatively such as lifestyle modification, topical or oral medical therapy, sclerosing injection, and rubber band ligation. An operation is indicated when non-operative approaches have failed or complications have occurred. Several surgical approaches for treating haemorrhoids have been introduced including haemorrhoidectomy, stapled haemorrhoidopexy, and doppler-guided haemorrhoidal artery ligation. However, postoperative pain is invariable and some of the surgical treatments potentially cause appreciable morbidity such as anal stricture, incontinence, and rectovaginal fistula. Hence, special precautions should be taken while performing a therapeutic intervention for haemorrhoids. At the same time, current haemorrhoidal treatment should also focus on how to minimise postoperative pain and recurrent haemorrhoids.

**SYMPOSIUM 9**

Rectal Cancer

**NEOADJUVANT THERAPY FOR RECTAL CANCER – WHO SHOULD GET CHEMORADIATION?**

April Camilla Roslani

Department of Surgery, University Malaya Medical Centre, Kuala Lumpur, Malaysia

Radiotherapy has an indisputable role in the prevention of local recurrence in locally advanced rectal cancer, supplementing the benefits of total mesorectal excision. Long course radiotherapy with concurrent chemotherapy in the neoadjuvant setting achieves higher complete response rates than short-course radiotherapy, and has been shown to improve rates of resection with clear margins, as well as reduce toxicity compared with adjuvant radiotherapy. Nonetheless, toxicity is considerable, impacting the quality of life of patients who, more and more, are surviving their disease, thanks to improvements in adjuvant systemic therapy.

Current selection criteria mandate neoadjuvant therapy in a large proportion of patients, particularly in a developing country such as Malaysia, where cancers present late. Additionally, presently available imaging tends to overstage tumours, expanding the numbers of patients falling into this category. Given the limited availability of oncology services, compliance may be compromised in the patients who would most benefit from it, while over-treating others. Better selection criteria, utilizing improved imaging techniques, real time data capture, and possibly prognostic biomarkers, as well as improved delivery, may help to optimize use of resources, and minimize the numbers of patients subjected to its adverse effects.



**SYMPOSIUM 10**  
Allied Health Professional Session (4)

**CONTINENT URINARY DIVERSION & NEOBLADDER**

Carol Stott

Stomal Therapy & Wound Care CNC, Prince of Wales Hospital, Randwick, New South Wales, Australia

When a person undergoes a Continent Urinary Diversion (CUD) or Neobladder operation the anatomy and physiology is altered significantly. Some of these patients are also dealing with a bladder cancer diagnosis. The pre and postoperative course these patients follow will be described in this paper and will include:

- Description of CUD and Neobladder operations
- Preoperative patient assessment and selection
- Preoperative education
- Postoperative education including learning catheterisation and irrigation
- Clean technique / Infection
- Mucus management
- 'Troubleshooting'

**SYMPOSIUM 10**  
Allied Health Professional Session (4)

**MALAYSIAN ENTEROSTOMAL THERAPY NURSING EDUCATION PROGRAM:  
CHALLENGES AND OPPORTUNITIES**

Mariam Mohd Nasir

Department of Nursing, Universiti Malaya Medical Centre, Kuala Lumpur, Malaysia

Enterostomal Therapy Nursing Education Program (ETNEP) is a program designed between 10 – 12 weeks to train registered nurses to become an Enterostomal Therapist(E.T.). These nurses then are given the license to practice as an Enterostomal Therapist(E.T.) to carry out extra roles and responsibilities to perform and manage stoma, wound and with or without continence care more competently and professionally.

A body known as World Council of Enterostomal Therapist (WCET) are a body that control the training and practice worldwide to ensure standard are achieved and patients and family right are being preserved.

Malaysian Enterostomal Therapy Nurses Association (METNA) has taken the initiative to train more nurses in this field as to ensure patient safety and also to provide high standard of care for them.

In the journey to fulfill the need of E.T., the program Director and her team has worked hard in preparing the curriculum, getting participants, arrangement for clinical practice etc. It is not an easy journey and in between it the organizer face a lot of difficulties and challenges but since the determination to ensure more Nurses can become E.T. they have successfully trained 31 newly graduated E.T. in 2013 and looking forward to train more Nurses in future.

Teamwork is very significant in any training such as E.T. The program is possible because the support from all Enterostomal Therapists, METNA, Colorectal Surgeons, others Allied Health Care and the sponsors from the trades.

The speaker will share more experiences during the conference.



**SYMPOSIUM 10**  
Allied Health Professional Session (4)

**SHARING EXPERIENCES AS A NEWLY QUALIFIED ENTEROSTOMAL THERAPIST (E.T.)**

Noorfariza binti Hussin

Malaysian ETNEP 2013, Universiti Malaya Medical Centre, Kuala Lumpur, Malaysia

Changes is necessary in life to better ourselves and also to equipped ourselves with the knowledge and skills necessary to ensure we are able to carry out our duties and responsibilities.

But the going is not easy all the times and many a times we have to face with many challenges to be where we want to be.

Being an Enterostomal Therapist or better known as E.T. is always a dream for me, this is to better myself in helping my patients. I was given the opportunity to join the Malaysian Enterostomal Therapy Nursing Education Program 2013 in my hospital which was organized by Malaysian Enterostomal Therapy Nurses Association (METNA).

It is indeed a challenging and new experience for me but I am certain to be able to be a good E.T and serve my patient more professionally.

Finally I had the title E.T next to my name! The speaker will share her experiences in her journey to become an E.T.

**SYMPOSIUM 10**  
Allied Health Professional Session (4)

**SHARING EXPERIENCES AS A NEWLY QUALIFIED ENTEROSTOMAL THERAPIST (E.T.)**

Azizan Mohd Isa

Enterostomal Therapist (ET) / Nurse Educator, Allied Health Institution, Johor Bahru, Johor, Malaysia

The speaker will be sharing her experiences as a newly qualified Enterostomal Therapist (E.T.) in three different aspects, which is knowledge, skill and her level of confidence in teaching about Enterostomal Therapy Nursing.

As a Nurse Educator, she is expected to know everything but that is not so most of the time especially Enterostomal Therapy Nursing (ETN). She has no problem teaching her students in her field of expertise, which is cancer nursing since she is highly qualified in Oncology and Cancer Nursing for nearly 10 years.

But when comes to Stomacare, she realizes that she needs to further learn about it and the opportunity comes at the right time for her when she was given the offer to join the Malaysian Enterostomal Therapy Nursing Education Program (Malaysian ETNEP), organized by Malaysian Enterostomal Therapy Nurses Association (METNA), a 12 weeks course that covers stoma, wound and continence care.

Ms Azizan will be sharing that experience with all during the conference and her joy of becoming an Enterostomal Therapist(E.T.)



**PLENARY 4**

## **ANTIBIOTIC STEWARDSHIP PROGRAMME: IMPROVING OUTCOMES IN AN ERA OF MULTIDRUG RESISTANCE**

Adrian Brink

Department of Clinical Microbiology, Ampath National Laboratory Services, Milpark Hospital, Parktown, Johannesburg, South Africa

Bacterial resistance in clinically important pathogens has reached alarming rates and exerts a significant impact on clinical outcomes. This phenomenon is longer confined to the hospital setting alone and will continue to worsen if not addressed, due to the fact that no antimicrobial options are on the immediate horizon.

The specific MDR, XDR and pan-drug resistant (PDR) bacteria that necessitate, antibiotic stewardship or antibiotic conservation as a matter of urgency, are the Gram-negative pathogens, in particular extended-spectrum  $\beta$ -lactamase (ESBL) producing and/or carbapenemase-producing Enterobacteriaceae (e.g. *Escherichia coli* and *Klebsiella pneumoniae*). Such resistance is a consequence of inappropriate prior antibiotic use which include homogenous (always the same agent e.g. fluoroquinolones or carbapenems) and excessive use (e.g. routine combination therapy), prescribed at incorrect doses (e.g. under dosing) for a long duration.

Multiple ASP strategies have been shown to improve antibiotic utilization and hence, bacteriological and clinical outcome. In fact, several recent studies have demonstrated in one of them, namely antibiotic heterogeneity and diversity as opposed to antibiotic homogeneity, the favourable impact on mortality, length of stay (incl ICU stay) and resistance rates. These results suggest a new approach to choosing antibiotics, that is patient specific with a focus on using multiple agents appropriately, and that subsequently leads to prescribing diversity. Furthermore, within an ASP "team", surgeons represent a crucial specialty; without source control antibiotic conservation is not possible.

### **PANEL DISCUSSION**

#### **Minimally Invasive Surgery**

## **NOTES. IS IT A WORTHY EFFORT?**

A Fichera

University of Washington Medical Center, Seattle, WA, USA

Natural Orifice Transluminal Endoscopic Surgery (NOTES), involves passing surgical instruments and the camera through a natural orifice, such as the stomach or the vagina, to perform surgery. By avoiding major incisions it is hypothesized that patients may recover more quickly, experience less pain and have no visible scars on their abdomen while the risk of post-operative complications is not increased.

During this brief discussion:

- 1) We will review the limited available data on "natural orifice" colorectal surgery.
- 2) We will emphasize sound surgical principles that should be respected and followed when performing a "natural orifice" surgery.
- 3) We will look at the potential future application of this approach.



**PANEL DISCUSSION**  
Minimally Invasive Surgery

**DEVELOPMENT OF A MULTI-CHANNEL PORT (X-GATE®), BJ NEEDLE®, AND DRACO® TO FACILITATE SAFE REDUCED PORT SURGERY: HOW TO REVIVE “THE LOST TRIANGLE”**

Eiji Kanehira, Takashi Tanida, Aya Kamei, Masafumi Nakagi, Amane Hideshima  
Department of Surgery, Medical Topia Soka, Japan

**BACKGROUND**

Technical difficulties in pure single incision endoscopic surgery should be mainly attributed to loss of the manipulation angle between the main operating instruments (“the lost triangle”). To overcome those difficulties the authors have been developing some new instruments including a multi-channel port, needle instruments, and double bendable forceps. Herein we introduce those new instruments and its performance during our reduced port surgery.

**METHODS**

Since 2009 we have developed a multi-channel port “x-Gate®”, in cooperation with Sumitomo Bakelite, “BJ needle®” series ( series of 2mm instruments) in cooperation with Niti-On Company, and a double bendable forceps “DraCo®” in cooperation with Futaku Precision Machinery. By 2013 x-Gate® and BJ needle® have been commercialized, while DraCo® is still under development. In human operation we have used x-Gate® and BJ needle® series. Instead of DraCo® so far we use Snowden Spencer® ( a single bendable forceps) to revive the lost triangle.

**RESULTS**

Over the past 5 years we have used those new instruments in more than 250 cases including cholecystectomy, wedge resection of the stomach, appendectomy, TAPP, splenectomy, colectomy, and so on. The instruments functioned well and were not broken during the operation, showing enough stability and safety. Cosmetic impression of the pin-pointed scar after puncturing BJ needle® was good. The conflicts between the instruments were minimized. The performance of the forceps seemed much better than the parallel situation in pure single incision endoscopic surgery, due to revived manipulation angles.

**CONCLUSIONS**

The combination of a new multi-channel port, a bendable forceps, and a needle instrument could stabilize the techniques during reduced port surgery and facilitate safe operation.



**POST-CONGRESS WORKSHOP**

**MULTIDISCIPLINARY MANAGEMENT. TO MDT OR NOT TO MDT**

A Fichera

University of Washington Medical Center, Seattle, WA, USA

Multidisciplinary management of inflammatory bowel disease is mandatory given the complexity of both medical and surgical available options and the importance of coordinating treatments. A modern approach is to discuss cases in a multidisciplinary team conference. By having all the involved parties in the same room, informed decisions and prompt initiation of treatment are easily achieved.

During this brief discussion:

- 1) We will review the experience of an IBD center in the US in managing these patients in a multidisciplinary fashion.
- 2) We will emphasize the role of the different specialties involved.
- 3) We will look at the steps necessary to implement an MDT.

**POST-CONGRESS WORKSHOP**

**CASE PRESENTATIONS: IBD SURGERY. MINEFIELD OR SOLUTION?**

A Fichera

University of Washington Medical Center, Seattle, WA, USA

During this case presentation:

- 1) We will review complex IBD cases that will emphasize a multidisciplinary team approach.
- 2) We will discuss the role of minimally invasive surgery, fecal diversion, and staged procedures.
- 3) We will look at outcomes in terms of presentation of intestinal length, quality of life and recurrence rates.





## BEST POSTER AWARD PRESENTATIONS

- PP01 **FACTORS INFLUENCING DELAYED REFERRAL TO TERTIARY CENTRE FOR COLONOSCOPY AMONG PATIENTS WITH ALARMING SYMPTOMS OF COLORECTAL CANCER** 38  
Yang, C W Law, A A Malik, H Y Chong, A C Roslani  
University of Malaya, Kuala Lumpur, Malaysia
- PP02 **DOES THE PRE-OPERATIVE USE OF PROBIOTIC PREVENT ILEUS IN PATIENTS WITH COLORECTAL CANCER AFTER SURGERY? A RANDOMIZED, DOUBLE- BLIND, PLACEBO-CONTROLLED TRIAL** 39  
C K Tan, K F Chin, A A Malik, Sanmugapriya, S Said, A C Roslani  
University of Malaya, Kuala Lumpur, Malaysia
- PP03 **COMPARATIVE PROSPECTIVE STUDY BETWEEN EXCISION AND LIGATION OF THE EXTERNAL FISTULA TRACT (ELEFT) TO LIFT PROCEDURE LONG TERM RESULTS AND FUNCTIONAL OUTCOME** 40  
F Shabeeb, Azmi M Nor, M Salehudin C Z  
Colorectal Unit, Department of Surgery, Faculty of Medicine, International Islamic University Malaysia, Kuantan, Pahang, Malaysia
- PP04 **IDENTIFICATION OF ALPHA-1 ADRENERGIC RECEPTOR IN HEMORRHOID TISSUE** 41  
Choon Aik Ho<sup>1</sup>, Koon Khee Chan<sup>1</sup>, Ismail Sagap<sup>2</sup>, Noraida Khalid<sup>1</sup>  
<sup>1</sup>Hospital Sultanah Aminah, Johor Bahru, Johor, Malaysia  
<sup>2</sup>Hospital Universiti Kebangsaan Malaysia, Kuala Lumpur, Malaysia
- PP05 **RANDOMISED CONTROL TRIAL ON ASSOCIATION OF LENGTH OF TIME TO ABSTINENCE FROM SOLID FOOD IN BOWEL PREPARATION TO CLEANLINESS OF THE BOWEL IN PATIENTS UNDERGOING ELECTIVE COLONOSCOPY** 42  
H P Loh, Dayang A, Jasiah  
Hospital Tuanku Jaafar, Seremban, Negeri Sembilan, Malaysia  
Universiti Kebangsaan Malaysia Medical Centre, Kuala Lumpur, Malaysia
- PP06 **COMPARISM OF THE EFFICACY OF BOWEL PREPARATION FOR COLONOSCOPY AT DIFFERENT TIME AMONG PATIENTS THAT UNDERGO COLONOSCOPY IN HOSPITAL SERDANG IN 2013** 43  
Nadia A<sup>1</sup>, Chin W P<sup>1</sup>, Tikfu G<sup>2</sup>, M O Myint<sup>2</sup>, Tong S W<sup>2</sup>  
<sup>1</sup>Faculty of Medicine & Health Sciences, University Putra Malaysia, Serdang, Selangor, Malaysia  
<sup>2</sup>Department of Surgery, Faculty of Medicine & Health Sciences, University Putra Malaysia, Serdang, Selangor, Malaysia
- PP07 **COMPLIANCE TO CHEMOTHERAPY AND RADIOTHERAPY IN COLORECTAL CANCER PATIENTS: A 5-YEAR UMMC EXPERIENCE** 44  
Khai-Yeong Teh<sup>1</sup>, April Camilla Roslani<sup>1,2</sup>, Chee-Wei Law<sup>1</sup>, Mastura Md Yusof<sup>3</sup>  
<sup>1</sup>Department of Surgery, Universiti Malaya Medical Centre, Kuala Lumpur, Malaysia  
<sup>2</sup>University of Malaya Cancer Research Institute, Kuala Lumpur, Malaysia  
<sup>3</sup>Department of Clinical Oncology, Universiti Malaya Medical Centre, Kuala Lumpur, Malaysia



## POSTER PRESENTATIONS

- PP08 **INTESTINAL OBSTRUCTION WITH HEMORRHAGIC TWIST: A CASE SERIES** 45  
Aidil Faizul bin Abdul Rahim  
Jabatan Pembedahan, Hospital Tengku Ampuan Afzan, Kuantan, Pahang, Malaysia
- PP09 **PEUTZ-JEGHERS SYNDROME WITHOUT MUCOCUTANEOUS PIGMENTATION. A CASE REPORT** 46  
Aizat Sabri I, Lo G Y, Junaidi AI, Clement Edward  
Hospital Tuanku Fauziah, Kangar, Perlis, Malaysia
- PP10 **COLONIC STENTING VERSUS EMERGENCY SURGERY IN LEFT SIDED COLONIC TUMORS** 47  
Devindran A/L Manoharan<sup>1</sup>, Manjit Singh<sup>2</sup>, Ausama A Malik<sup>1</sup>, H Y Chong<sup>1</sup>, A C Roslani<sup>1</sup>  
<sup>1</sup>University of Malaya, Kuala Lumpur, Malaysia  
<sup>2</sup>Hospital Pulau Pinang, Penang, Malaysia
- PP11 **CLINICAL SHORT-TERM OUTCOMES OF LASER HEMORRHOIDOPLASTY: A MULTICENTER STUDY** 48  
Hoong-Yin Chong<sup>1</sup>, April C Roslani<sup>1</sup>, Sandip Kumar<sup>1</sup>, Ausama A Malik<sup>1</sup>, Chee-Wei Law<sup>1</sup>, Siew-How Chan<sup>3</sup>, Vijeyasingam Rajasingam<sup>2</sup>, Jeyaratnam Kasipillai<sup>2</sup>  
<sup>1</sup>Surgery, Universiti Malaya Medical Centre, Kuala Lumpur, Malaysia  
<sup>2</sup>Surgery, Assunta Hospital, Petaling Jaya, Selangor, Malaysia  
<sup>3</sup>Surgery, Pantai Hospital Ampang, Kuala Lumpur, Malaysia
- PP12 **A CASE REPORT OF FAP WITH YOUNG AGE PRESENTATION OF COLON CANCER** 49  
Huzairi Y, Ahmad S, Mulianis M N, Hidayah M S  
Hospital Raja Perempuan Zainab II, Kota Bharu, Kelantan, Malaysia
- PP13 **A CASE REPORT OF COMPLETE PATHOLOGICAL RESPONSE AFTER NEOADJUVANT CHEMORADIOTHERAPY FOR LOCALLY ADVANCED RECTAL CANCER** 49  
Huzairi Y, Ahmad S, Hidayah M S, Azihan Z  
Hospital Raja Perempuan Zainab II, Kota Bharu, Kelantan, Malaysia
- PP14 **EXTRACOLONIC MANIFESTATION OF FAMILIAL ADENOMATOSIS POLYPOSIS: MANAGEMENT DILEMMA** 50  
N S Amin<sup>1</sup>, S M Ikhwan<sup>2</sup>, H I M Siti Rahmah<sup>2</sup>, Z Zaidi<sup>2</sup>, M M Faris<sup>2</sup>, W Z W Zainira<sup>2</sup>, S Hassan<sup>2</sup>  
<sup>1</sup>Department of Surgery, School of Medical Sciences, Universiti Malaysia Sabah, Sabah, Malaysia  
<sup>2</sup>Department of Surgery, School of Medical Sciences, Universiti Sains Malaysia Health Campus, Kubang Kerian, Kelantan, Malaysia
- PP15 **LIPOMATOUS CAECAL POLYP CAUSING ILEOCAECAL INTUSSUSCEPTION IN AN ELDERLY LADY: A CASE REPORT** 50  
Ikhwan Sani Mohamad, Kenneth Voon Kher Ti, Zaidi Zakaria, Syed Hassan Syed Aziz  
Department of Surgery, School of Medical Sciences, Universiti Sains Malaysia Health Campus, Kubang Kerian, Kelantan, Malaysia



## POSTER PRESENTATIONS

- PP16 CO-EXISTING ABDOMINAL TUBERCULOSIS AND MUCINOUS ADENOCARCINOMA OF COLON: A CASE REPORT** 51  
S M Ikhwan<sup>1</sup>, L S Bob<sup>1</sup>, A A M Zin<sup>2</sup>, Z Zaidi<sup>1</sup>, S Hassan<sup>1</sup>  
<sup>1</sup>Department of Surgery, School of Medical Sciences Universiti Sains Malaysia Health Campus, Kubang Kerian, Kelantan, Malaysia  
<sup>2</sup>Department of Pathology, School of Medical Sciences Universiti Sains Malaysia Health Campus, Kubang Kerian, Kelantan, Malaysia
- PP17 LOWANTERIOR RESECTION FOR ADENOCARCINOM OF RECTAL PROLAPSE** 51  
I Ismaliza, N Amri, W Khamizar  
Hospital Sultanah Bahiyah, Alor Setar, Kedah, Malaysia
- PP18 AN AUDIT ON SURGICAL INTERVENTION FOR COMPLICATED COLONIC DIVERTICULAR DISEASE IN HOSPITAL MELAKA: 7 YEARS DURATION** 52  
J H Lai, S L Teh, A H Y Amar  
Surgical Department, Hospital Melaka, Melaka, Malaysia
- PP19 3 YEARS OF EXPERIENCE WITH FISTULA-IN-ANO REPAIR IN HOSPITAL TENGGU AMPUAN AFZAN, KUANTAN, PAHANG: A SURGICAL CHALLENGE** 53  
M Salehudin C Z, Azmi M Nor, Fadel S  
Colorectal Unit, Department of Surgery, Faculty of Medicine, International Islamic University Malaysia, Kuantan, Pahang, Malaysia
- PP20 UNUSUAL PRESENTATION OF ISCHIORECTAL (HORSESHOE TYPE) ABSCESS** 54  
Noor Ezmas Mahno<sup>1</sup>, David Ong<sup>2</sup>, Fadeel Shabeeb<sup>1</sup>, Azmi Md Nor<sup>1</sup>  
<sup>1</sup>International Islamic University of Malaysia, Kuantan, Pahang, Malaysia  
<sup>2</sup>Hospital Tengku Ampuan Afzan, Kuantan, Pahang, Malaysia
- PP21 MESENTERIC CYST OF DESCENDING COLON: A RARE SUBTYPE** 55  
Noor Ezmas Mahno<sup>1</sup>, David Ong<sup>2</sup>, Fadeel Shabeeb<sup>1</sup>, Azmi Md Nor<sup>1</sup>  
<sup>1</sup>International Islamic University of Malaysia, Kuantan, Pahang, Malaysia  
<sup>2</sup>Hospital Tengku Ampuan Afzan, Kuantan, Pahang, Malaysia
- PP22 GANGRENOUS COLON : POLYARTERITIS NODOSA OF THE GASTROINTESTINAL TRACT** 55  
F J Ruhi<sup>1,2</sup>, I Sagap<sup>2</sup>  
<sup>1</sup>Universiti Sains Islam Malaysia, Kuala Lumpur, Malaysia  
<sup>2</sup>University Kebangsaan Malaysia, Kuala Lumpur, Malaysia
- PP23 EXTENSIVE COLONIC ISCHEMIA – REPORT OF A CASE** 56  
Sarmukh S<sup>1</sup>, M O Myint<sup>2</sup>, Shaker A H<sup>2</sup>  
<sup>1</sup>Hospital Serdang, Selangor, Malaysia  
<sup>2</sup>University Putra Malaysia, Serdang, Selangor, Malaysia
- PP24 ACUTE COLONIC PSEUDO-OBSTRUCTION (OGILVIE'S SYNDROME) – A RARE COMPLICATION IN POST TAHBSO AND SIGMOIDECTOMY** 57  
Sarmukh S<sup>1</sup>, M O Myint<sup>2</sup>, Salleh M<sup>2</sup>, Shaker A H<sup>2</sup>  
<sup>1</sup>Department of Surgery, Hospital Serdang, Selangor, Malaysia  
<sup>2</sup>Department of Surgery, University Putra Malaysia, Selangor, Malaysia



## POSTER PRESENTATIONS

- PP25 PREOPERATIVE CARCINOEMBRYONIC ANTIGEN; A PROGNOSTIC INDICATOR OF TUMOR GRADE** 58  
Satkunan M, D Z Andee, Z Zaidi, S Hassan  
Department of Surgery, School of Medical Sciences, Universiti Sains Malaysia Health Campus, Kubang Kerian, Kelantan, Malaysia
- PP26 RECURRENT COLORECTAL CANCER AT STOMA SITE WITH PALLIATIVE STENTING OVER STOMA: A CASE REPORT** 58  
Syafiq H M M, Fahmey M S, Imran A K  
Department of Surgery, Hospital Seberang Jaya, Seberang Prai, Penang, Malaysia
- PP27 COLONIC ADENOCARCINOMA METASTASIS TO OVARIES OR PRIMARY OVARIAN TUMOURS WITH COLON METASTASIS: HOW TO DETERMINE IT?** 59  
Syafiq H, Fahmey M S, Imran A K  
Department of Surgery, Hospital Seberang Jaya, Seberang Prai, Penang, Malaysia
- PP28 KANA FRUIT: A RARE CAUSE OF SMALL BOWEL OBSTRUCTION** 59  
K N Tan, Nil Amri M Kamil, Wan Khamizar W Khazim  
Hospital Sultanah Bahiyah, Alor Setar, Kedah, Malaysia
- PP29 PRIMARY COLONIC LYMPHOMA PRESENTING AS PERFORATED VISCUS** 59  
K N Tan<sup>1</sup>, H L Hoo<sup>2</sup>, Nil Amri M Kamil<sup>1</sup>, Wan Khamizar W Khazim<sup>1</sup>  
<sup>1</sup>Hospital Sultanah Bahiyah, Alor Setar, Kedah, Malaysia  
<sup>2</sup>Hospital Enche' Besar Hajjah Khalsom, Kluang, Johor, Malaysia
- PP30 A CASE OF SIGNET-RING CELL CARCINOMA OF CAECUM PRESENTED LIKE ACUTE APPENDICITIS** 60  
K N Tan<sup>1</sup>, H L Hoo<sup>2</sup>, Nil Amri M Kamil<sup>1</sup>, Wan Khamizar W Khazim<sup>1</sup>  
<sup>1</sup>Hospital Sultanah Bahiyah, Alor Setar, Kedah, Malaysia  
<sup>2</sup>Hospital Enche' Besar Hajjah Khalsom, Kluang, Johor, Malaysia
- PP31 A PREVALENT DISEASE OFTEN OVERLOOKED** 60  
Nadia Nafasha Baharudin, K N Tan, Nil Amri M Kamil, Wan Khamizar W Khazim  
Hospital Sultanah Bahiyah, Alor Setar, Kedah, Malaysia
- PP32 RECTAL FOREIGN BODY: SURPRISE BEYOND THE CUP** 60  
K N Tan, Nil Amri M Kamil, Wan Khamizar W Khazim  
Hospital Sultanah Bahiyah, Alor Setar, Kedah, Malaysia
- PP33 LAPAROSCOPIC ASSISTED TWO PORTS APPENDICECTOMY FOR FREE APPENDIX "ANY SURGICAL MEDICAL OFFICER CAN DO"** 61  
Mutyala Vinod Kumar, Yiu Maeng Tang, Choon Woon Ngo  
Hospital Duchess of Kent, Sandakan, Sabah, Malaysia



**BEST POSTER AWARD PRESENTATIONS**  
PP01

## **FACTORS INFLUENCING DELAYED REFERRAL TO TERTIARY CENTRE FOR COLONOSCOPY AMONG PATIENTS WITH ALARMING SYMPTOMS OF COLORECTAL CANCER**

Yang, C W Law, A A Malik, H Y Chong, A C Roslani  
University of Malaya, Kuala Lumpur, Malaysia

### **BACKGROUND**

Colorectal cancer is the second most common cancer in Malaysia. Besides, it is the commonest cancer in male and second commonest cancer in female, the prognosis of colorectal is good if it is detected at the early stage. Unfortunately, population-based colorectal cancer screening is not available in Malaysia. Hence, the detection of colorectal cancer is dependent on patients' health-related help-seeking behavior, and recognition of significant symptoms by primary care services, the major gate-keepers in the healthcare system, potentially leading to delayed diagnosis. The objective of this study was to identify the pre-hospital factors which influenced delays in tertiary centre referrals for suspected colorectal cancer.

### **METHODS**

This cross sectional study was carried out in Hospital Tengku Ampuan Rahimah, Klang. Patients referred for colorectal cancer alarm symptoms from January 2012 till December 2012 were reviewed to ascertain patterns of help-seeking behavior. Logistic multivariate regression analysis was used to determine factors associated with delayed referral.

### **RESULTS**

A total of 130 patients were included. Socio-demographics such as age, gender, ethnicity or educational level did not delay medical help-seeking. The presence of alarm symptoms, such as rectal bleeding, did not alert patients to seek help earlier. However, hospital emergency departments tended to refer patients earlier for further investigation compared with private or government clinics ( $p < 0.05$ ). In additional, logistic regression multivariate analysis showed that poor bedside examination tended to cause delays in referring to tertiary centre ( $p < 0.05$ )

### **CONCLUSION**

Primary care practice is the main factor causing delay in further investigation of patients with alarm symptoms. Further study is needed to identify appropriate measures to improve the referral system.



**BEST POSTER AWARD PRESENTATIONS**  
PP02

**DOES THE PRE-OPERATIVE USE OF PROBIOTIC PREVENT ILEUS IN PATIENTS WITH COLORECTAL CANCER AFTER SURGERY? A RANDOMIZED, DOUBLE- BLIND, PLACEBO-CONTROLLED TRIAL**

C K Tan, K F Chin, A A Malik, Sanmugapriya, S Said, A C Roslani  
University of Malaya, Kuala Lumpur, Malaysia

**BACKGROUND**

Ileus is the commonest expected consequence after abdominal surgery. Studies have shown that the longest duration of ileus occurs after colonic surgery. This study aims to evaluate the efficacy of pre-operative use of probiotics in preventing ileus in patients undergoing surgery for colorectal cancer.

**METHODS**

This is a randomized, double-blind placebo-controlled trial. Patients were randomised to receive probiotics or placebo for 7 days before surgery. The primary outcome of interest was time to return of normal gut function, with a secondary outcome of hospital length of stay.

**RESULTS**

Twenty patients were randomised to each group. The probiotic group demonstrated statistically significant earlier return of normal gut function compared with controls [124.6 hours (80- 250 hours) versus 149.9 hours (94- 220hours),  $p = 0.021$ ]. In addition, the length of hospital stay was shorter for the probiotic group compared to placebo group [9.2 days (6.33 - 12.07 days) versus 12.6 days (10.06-15.14 days),  $p = 0.012$ ].

**CONCLUSION**

Pre-operative administration of probiotics promotes earlier return of gut function and shorter hospital stay in patients undergoing surgery for colorectal cancer



**BEST POSTER AWARD PRESENTATIONS**  
PP03

**COMPARATIVE PROSPECTIVE STUDY BETWEEN EXCISION AND LIGATION OF THE  
EXTERNAL FISTULA TRACT (ELEFT) TO LIFT PROCEDURE  
LONG TERM RESULTS AND FUNCTIONAL OUTCOME**

F Shabeeb, Azmi M Nor, M Salehudin C Z

Colorectal Unit, Department of Surgery, Faculty of Medicine, International Islamic University Malaysia, Kuantan, Pahang, Malaysia

**PURPOSE**

This study was designed to assess the eLEFT as new promising anal sphincter-saving technique the treatment of fistula in ano.

**METHODS**

This a prospective observational study of patients with fistula-in-ano. A total of 40 patients from 2010 to 2013 underwent fistula repair under elective operation list identified. Demographic data of patients were assessed. All Patient subjected to endoanal ultrasound (EAUS) and Anal Manometry prior to the surgery to determine types of fistula based on Park's classification and to assess anal function prior to surgery. Follow up was made post-operatively to assess healing time, recurrence rate and anal functions outcomes.

**RESULTS**

Mean age of the patient presented to our center was 43.5 year old. Intersphincteric and transsphincteric type of fistula account 42.5% and 30% respectively. Two most common methods of fistula repair were core fistulectomy and LIFT which account for 52.5% and 30% respectively. 75% of patients achieved primary healing after the procedure. Mean healing duration of those who underwent core fistulectomy was 7 weeks and LIFT was 16 weeks. 25% of patients subjected to core fistulectomy failed, either had persistent or recurrence of the disease whereas LIFT had 28.6% of failure rate. No clinically significant morbidity was noted in any of the 40 patients

**CONCLUSIONS**

The eLEFT has achieved significant success rate with good anal function outcome. It is effective for the long-term closure of complex cryptoglandular fistulas. The high success rate in patients treated with this technique make this procedure a good option in treating patient



**BEST POSTER AWARD PRESENTATIONS**  
PP04

## **IDENTIFICATION OF ALPHA-1 ADRENERGIC RECEPTOR IN HEMORRHOID TISSUE**

Choon Aik Ho<sup>1</sup>, Koon Khee Chan<sup>1</sup>, Ismail Sagap<sup>2</sup>, Noraida Khalid<sup>1</sup>

<sup>1</sup>Hospital Sultanah Aminah, Johor Bahru, Johor, Malaysia

<sup>2</sup>Hospital Universiti Kebangsaan Malaysia, Kuala Lumpur, Malaysia

### **OBJECTIVE**

1. To Identify the presence of Alpha-1 Adrenergic receptor in Hemorrhoid Tissue
2. To analyse the association between the Alpha-1 Adrenergic receptor and micronised flavonoid

### **METHOD**

Prospective observational study using immunofluorescence method on haemorrhoid tissue from patient with second to fourth degree haemorrhoid from June 2012 to November 2013. The primary outcome was identifying presence of Alpha-1 Adrenergic receptor in haemorrhoid tissue.

### **RESULT**

Total of 34 patients were recruited. There were 18(52.9%) Malay, 14(41.2%) Chinese, 2(5.9%) others. 15(44.1%) were Male and 19(55.9%) were female. 4(11.8%) were second degree disease, 14(41.2%) were third degree disease and 16(47.1%) were fourth degree disease. 15(44.1%) did not take micronized flavonoid within 6 months prior to inclusion and 19(55.9%) took micronized flavonoid before. Immunofluorescence study showed 8(23.5%) haemorrhoid tissue didn't contain Alpha-1 Adrenergic receptor, however 26(76.5%) contained receptor. 2(5.9%) of the receptors produced signal strength at 1+, 12(35.3%) at 2+, another 12(35.5%) at 3+. Of those patients who used micronised flavonoid within 6 months of surgery, there was no correlation between presence of Alpha-1 Adrenergic receptors and subjective clinical improvement of symp-toms( Pearson Chi-Square Test = 0.656).

### **CONCLUSION**

This pilot study showed that Alpha-1 Adrenergic Receptor is detected in the haemorrhoid tissue in majority of the patient. However there was no correlation between presence of the receptor and subjective clinical improvement of symptoms with usage of micronized flavonoid. This may suggest that micronized flavonoid does help in relieving symptoms even in absence of the receptors. A larger sample in the future would be useful to see the quantitative analysis of clinical improvement with micronised flavonoid in the presence of Alpha-1 Adrenergic receptors.





**BEST POSTER AWARD PRESENTATIONS**  
PP05

**RANDOMISED CONTROL TRIAL ON ASSOCIATION OF LENGTH OF TIME TO ABSTINENCE FROM SOLID FOOD IN BOWEL PREPARATION TO CLEANLINESS OF THE BOWEL IN PATIENTS UNDERGOING ELECTIVE COLONOSCOPY**

H P Loh, Dayang A, Jasiah

Hospital Tuanku Jaafar, Seremban, Negeri Sembilan, Malaysia  
Universiti Kebangsaan Malaysia Medical Centre, Kuala Lumpur, Malaysia

**BACKGROUND**

Elective colonoscopy has become an essential for screening of colonic pathology. However, no formal study has been performed to determine how long a patient should withhold solid meal in bowel preparation prior to an out-patient colonoscopy. The more time a patient is allowed to continue his normal diet, the greater is the patient's acceptance and compliance at undergoing bowel preparation. Methodology: A randomized prospective control trial was carried out for patients who underwent elective colonoscopy at Hospital Tuanku Jaafar Seremban from January until July 2013. Patients were randomized into 2 groups. Group A patients had abstinence from solid diet 24 hours (last solid meal was breakfast the day before colonoscopy) whilst group B patients had abstinence from solid diet 14 hours prior to colonoscopy (last solid meal was dinner the day before colonoscopy). Oral intake of sodium phosphosoda was standardized. Boston Bowel Preparation Scale (BBPS) was used to grade the bowel cleanliness. Score more than 2 was considered clean bowel preparation. Primary objective was to compare bowel cleanliness with regards to the duration of abstinence from solid food. Secondary objective was to compare the colonoscopy completion rate between both groups. Results: 178 patients (each arms 89 patients) were recruited for this study. Mean bowel cleanliness score for group A is 3 whilst Group B is 2.5. Both groups had good bowel cleanliness scores. Although comparison analysis showed significant difference ( $p=0.006$ ), there was no difference in the completion rate for the two groups ( $p=0.052$ ). Conclusion: Abstinence from solid food for 24 or 14 hours prior to colonoscopy both yielded clean bowel preparation, where colonoscopy able to completed until caecum. This result showed patients can take solid meals up to 14 hours with bowel preparation without the need to over-starve them, especially amongst the elderly, Diabetes Mellitus, Gastritis or Hypertension patients.



**BEST POSTER AWARD PRESENTATIONS**  
PP06

## **COMPARISON OF THE EFFICACY OF BOWEL PREPARATION FOR COLONOSCOPY AT DIFFERENT TIME AMONG PATIENTS THAT UNDERGO COLONOSCOPY IN HOSPITAL SERDANG IN 2013**

Nadia A<sup>1</sup>, Chin W P<sup>1</sup>, Tikfu G<sup>2</sup>, M O Myint<sup>2</sup>, Tong S W<sup>2</sup>

<sup>1</sup>Faculty of Medicine & Health Sciences, University Putra Malaysia, Serdang, Selangor, Malaysia

<sup>2</sup>Department of Surgery, Faculty of Medicine & Health Sciences, University Putra Malaysia, Serdang, Selangor, Malaysia

### **BACKGROUND**

Colorectal cancer is the most common leading cause of death in cancer worldwide. While in Malaysia, colorectal cancer has overtaken lung cancer as the second most common cancer. Colonoscopy plays an important role in detection of colorectal cancer and efficacy of colonoscopy depends much on good bowel preparation.

### **OBJECTIVE**

The aim of this study is to compare the timing of bowel preparation and its effects and efficacy on the quality of colonoscopy among patients that undergoes conventional bowel preparation (2pm/ 8pm) and the other group of patients who undergoes proposed bowel preparation (6pm/6am).

### **METHODS**

A clinical trial study was conducted by assessing primary data for June and July 2013 through convenience sampling in Colonoscopy Clinic in Hospital Serdang. Data recorded were regarding patients undergo colonoscopy based on medical records and socio-demographic data pertaining age, gender and ethnicity. All data were recorded in standardised proforma.

### **RESULTS**

There were a total of 110 data respectively for both conventional group and proposed group recorded. Demographic studies showed 63 (57.3%) patients were under 60 years old, 61 (55.5%) of them were male, and 48 (44%) of them were Malays. For the patients undergo colonoscopy, majority of them 86 (78.2%) had good bowel preparation and 96 (87.3%) of them with high efficacy of bowel preparation. The result of Chi-Square Test shows that the timing of the bowel preparation are significantly associated with the efficacy of the bowel preparation and quality of the colonoscopy ( $p < 0.05$ ).

### **CONCLUSION**

We can conclude that proposed bowel preparation regimen (6pm one day before colonoscopy and 6am on the same day of colonoscopy) is the best timing to enhance the efficacy of bowel preparation and quality of colonoscopy.



**BEST POSTER AWARD PRESENTATIONS**  
PP07

## **COMPLIANCE TO CHEMOTHERAPY AND RADIOTHERAPY IN COLORECTAL CANCER PATIENTS: A 5-YEAR UMMC EXPERIENCE**

Khai-Yeong Teh<sup>1</sup>, April Camilla Roslani<sup>1,2</sup>, Chee-Wei Law<sup>1</sup>, Mastura Md Yusof<sup>3</sup>

<sup>1</sup>Department of Surgery, Universiti Malaya Medical Centre, Kuala Lumpur, Malaysia

<sup>2</sup>University of Malaya Cancer Research Institute, Kuala Lumpur, Malaysia

<sup>3</sup>Department of Clinical Oncology, Universiti Malaya Medical Centre, Kuala Lumpur, Malaysia

### **BACKGROUND**

The addition of various chemotherapy and/or radiotherapy regimes to surgery results in significant improvements in colorectal cancer survival and symptom control. Compliance to these regimes is of great importance in order to derive their full benefits, but measuring this is fraught with difficulty. There is little Malaysian data addressing this issue.

### **OBJECTIVES**

To measure the level of compliance to chemotherapy and radiotherapy among colorectal cancer patients, and to identify the reasons for non-compliance as well as patient and disease characteristics that predispose to non-compliance.

### **METHODS**

Records of colorectal cancer patients who had undergone chemotherapy and/or radiotherapy in UMMC between 2006 and 2010 were retrospectively reviewed. Compliance was defined as the successful completion of all prescribed regimes. Degrees of compliance, both overall and to each individual regime, as well as reasons for non-compliance were analyzed against patients' demographic and pathological characteristics.

### **RESULTS**

A total of 272 patients were analyzed. Of these, 56.6% were fully compliant to all prescribed chemotherapy and radiotherapy regimes. The commonest reason for non-compliance was medical complications, with gastrointestinal complications being most prevalent. Charlson's score (for co-morbidities) and stage of disease were significant predictors for non-compliance.

### **CONCLUSION**

There is room for improvement in terms of patient compliance to chemotherapy and radiotherapy. Special attention should be given to patients with multiple co-morbidities and advanced disease in terms of pre-treatment optimization to prevent non-completion of prescribed regimes.



**POSTER PRESENTATIONS**  
PP08

## **INTESTINAL OBSTRUCTION WITH HEMORHAGIC TWIST: A CASE SERIES**

Aidil Faizul bin Abdul Rahim  
Jabatan Pembedahan, Hospital Tengku Ampuan Afzan, Kuantan, Pahang, Malaysia

### **BACKGROUND**

Leaking abdominal aorta aneurysm is a life threatening condition and potentially fatal even with prompt intervention and treatment. A common scenario would be a hypertensive elderly presented as acute abdomen in hypovolemic shock with tense peritonitic abdomen. Intestinal obstruction otherwise occurs slightly delayed course of time with or without peritonitis and rarely associated with shock unless in severe septicemia.

### **OBJECTIVES**

To highlight that leaking abdominal aorta aneurysm can has atypical presentation and masquerade as an intestinal obstruction without the evidence of hemodynamic instability.

### **PATIENTS**

We presented two cases of leaking abdominal aorta aneurysm admitted to our center as hemodynamically stable intestinal obstruction at presentation. Both cases were posted for exploratory laparotomy, which later succumbed to leaking aneurysm.

### **RESULTS**

One patient succumbed in emergency department before able to push for emergency laparotomy and the diagnosis was made through bed side ultrasound whereas another patient died of intractable shock following laparotomy, aneursectomy, aorta-bifemoral bypass for massive hemoperitoneum.

### **CONCLUSIONS**

Leaking abdominal aortic aneurysm is a surgical emergency which usually manifested as acute abdomen with alarming hypovolemia requiring immediate resuscitation and intervention. Unfortunately it can mimic an intestinal obstruction. Without proper diagnosis of leaking AAA, patient prognosis is far more grieve.



**POSTER PRESENTATIONS**  
PP09

**PEUTZ-JEGHERS SYNDROME WITHOUT MUCOCUTANEOUS PIGMENTATION.  
A CASE REPORT**

Aizat Sabri I, Lo G Y, Junaidi Al, Clement Edward  
Hospital Tuanku Fauziah, Kangar, Perlis, Malaysia

**INTRODUCTION**

Peutz-Jeghers syndrome (PJS) is a rare familial disorder characterised by mucocutaneous pigmentation, gastrointestinal and extragastrointestinal hamartomatous polyps and an increased risk of malignancy. Peutz-Jeghers polyps in the bowel may result in intussusception. We present a patient with history of intestinal obstruction without mucocutaneous pigmentation.

**CASE REPORT**

We report a case of 17 years old Malay boy who previously healthy and no past medical history, presented with symptoms of acute intestinal obstruction. His complaints of generalized abdominal pain, profuse vomiting and abdominal distension for the past 3 days. No other complaints noted. Initial vital signs were stable and he did not shown any signs of sepsis. Clinical examination revealed a distended abdomen with tenderness at lower part of abdomen. Initial fluid resuscitation done and bowel decompression using Ryle's tube shows feculent material drained out. Due to persistent pain and increase abdominal distension. An exploratory laparotomy was carried out. Intraoperatively noted there was an intussusception of terminal ileum into cecum due to polyp at 20 cm from terminal ileum. Noted also ischemic segment of terminal ileum measuring 7 cm. limited right hemicolectomy was performed. His postoperative course was uneventful with complete resolution of the symptoms. Pathological examination of the polyps confirmed hamartomas with smooth muscle arborisation, compatible with Peutz Jeghers polyps.

**CONCLUSION**

Patients with PJS should be regularly and closely monitored, because of the increased risk of cancer and to reduce the number of laparotomies. Recent advances in genetic testing and capsule endoscopy should result in improved management of patients with PJS.



**POSTER PRESENTATIONS**  
PP10

## **COLONIC STENTING VERSUS EMERGENCY SURGERY IN LEFT SIDED COLONIC TUMORS**

Devindran A/L Manoharan<sup>1</sup>, Manjit Singh<sup>2</sup>, Ausama A Malik<sup>1</sup>, H Y Chong<sup>1</sup>, A C Roslani<sup>1</sup>

<sup>1</sup>University of Malaya, Kuala Lumpur, Malaysia

<sup>2</sup>Hospital Pulau Pinang, Penang, Malaysia

### **BACKGROUND**

Colorectal cancer is the second most common cancer in Malaysia and the third commonest cause of death due to carcinoma in Malaysia. Between 10 and 30% of the colorectal carcinomas present with acute obstruction, and the mortality and morbidity rates for emergency surgery are 15 and 50% respectively. Conventionally, surgical decompression via a defunctioning colostomy and/or resection is performed, but colonic stenting is an option that allows avoidance of peri-operative risks. This study aims to determine short-term outcomes of colonic stenting for malignant obstruction in a Malaysian setting.

### **METHODOLOGY**

This single-centre retrospective study was conducted in the Penang General Hospital. Records of all patients who had undergone either colonic stenting or emergency surgery for malignant intestinal obstruction from the 1st of January 2009 till the 31st of December 2011 were reviewed. Demographics and outcome data were extracted.

### **RESULTS**

Of the 84 patients included, 31 were stented, and 53 underwent surgery. The mean age of presentation was 64, with a male to female ratio of 1:117. Chinese was the predominant race affected, and in both groups the tumor was most often located in the sigmoid colon. Stented patients were more likely to avoid major complications compared to the surgery group (93.5% vs 51.9%). Stoma Rates was significantly higher in the surgery group as well where only 21.2% patients didn't have a stoma. The stenting group was associated with significantly lower days of admission as well as intensive care unit stay.

### **CONCLUSION**

Colonic stenting for malignant intestinal obstruction has superior short-term outcomes compared to surgery, and is safe and suitable to be used in the Malaysian setting.



**POSTER PRESENTATIONS**  
PP11

**CLINICAL SHORT-TERM OUTCOMES OF LASER HEMORRHOIDOPLASTY:  
A MULTICENTER STUDY**

Hoong-Yin Chong<sup>1</sup>, April C Roslani<sup>1</sup>, Sandip Kumar<sup>1</sup>, Ausama A Malik<sup>1</sup>, Chee-Wei Law<sup>1</sup>, Siew-How Chan<sup>3</sup>,  
Vijeyasingam Rajasingam<sup>2</sup>, Jeyaratnam Kasipillai<sup>2</sup>  
<sup>1</sup>Surgery, Universiti Malaya Medical Centre, Kuala Lumpur, Malaysia  
<sup>2</sup>Surgery, Assunta Hospital, Petaling Jaya, Selangor, Malaysia  
<sup>3</sup>Surgery, Pantai Hospital Ampang, Kuala Lumpur, Malaysia

**PURPOSE**

Laser hemorrhoidoplasty (LHP) utilizes thermal energy generated by a diode laser to treat symptomatic internal hemorrhoids. Early series have reported promising results, with little post-operative pain, short operating time, few serious post-operative complications and low recurrence rates. However, there are variations in the technique utilized. The aims of this study are to determine the short-term clinical outcomes of LHP and to ascertain if outcomes differed between patients with, and without, pedicle ligation.

**METHODS**

Patients from three institutions who underwent LHP between December 2011 and October 2013 were identified from a prospective database. Data analysed included demographics, severity, symptoms, operative technique, post-operative pain, complications and recurrence. Sub-analysis of patients with concurrent pedicle ligation, and without, was conducted. Statistical analysis was performed using the  $\chi^2$  test, with p values <0.05 considered statistically significant.

**RESULTS**

A total of 102 patients (59.8% male) of a mean age of 45 years were evaluated. The majority (62.7%) had third degree hemorrhoids. Median operative time was 24 (10-60) minutes and post-operative length of stay was 26 (2-168) hours. The median pain score 24 hours post-operatively was 0/10.

The overall complication rate was 26.5%, but most were self-limiting. The most common complication was post-operative swelling (16 patients; 15.7%). Post-operative bleeding was seen in nine patients (8.8%) at a median of 7 (1-14) days, three of whom required surgery and readmission. Four patients (3.9%) had moderate-to-severe pain (pain score of > 5/10) and two patients (2.0%) developed ulceration. Three patients (2.9%) had recurrence which was treated conservatively. Patients with pedicle ligation had a higher incidence of complications (33.3% vs. 7.4%; p=0.01), predominantly bleeding and swelling.

**CONCLUSIONS**

LHP shows promising short-term results with low complication and recurrence rates. Additional ligation of pedicles does not offer added benefits but may worsen outcomes.



**POSTER PRESENTATIONS**

PP12

## **A CASE REPORT OF FAP WITH YOUNG AGE PRESENTATION OF COLON CANCER**

Huzairi Y, Ahmad S, Mulianis M N, Hidayah M S  
Hospital Raja Perempuan Zainab II, Kota Bharu, Kelantan, Malaysia

### **INTRODUCTION**

Familial Adenomatous Polyposis (FAP) is a hereditary disorder where affected individuals will develop hundreds to thousands of adenomatous polyps throughout the GIT mainly in large bowel. These polyps may progress to carcinoma if left untreated.

### **CASE REPORT**

A 27 year old Malay lady was diagnosed to have FAP in April 2013 following screening colonoscopy. This was after her younger sister was diagnosed to have FAP. She had strong family history of colorectal cancer. Both her father and brother died due to colon cancer.

Biopsy of the most suspicious polyps in the sigmoid colon revealed adenomatous polyps. She undergo panproctocolectomy, ileal pouch and ileorectal anastomosis with covering ileostomy in November 2013.

HPE result showed moderately differentiated adenocarcinoma of the sigmoid colon in the background of adenomatous polyps. Three out of 44 lymphnodes were positive of cancer.

CT-scan thorax/abdomen/pelvis showed no distant metastasis.

### **DISCUSSION**

Most important step leading to diagnosis of a hereditary cancer syndrome like FAP is the compilation of thorough family history of cancer. Once diagnosis of FAP is established, all siblings should undergo screening colonoscopy. The onset of colorectal cancer in classic FAP at average age approximately 39 years. Earlier onset of cancer may be due to mutations associated with severe phenotype.

**POSTER PRESENTATIONS**

PP13

## **A CASE REPORT OF COMPLETE PATHOLOGICAL RESPONSE AFTER NEOADJUVANT CHEMORADIOTHERAPY FOR LOCALLY ADVANCED RECTAL CANCER**

Huzairi Y, Ahmad S, Hidayah M S, Azihan Z  
Hospital Raja Perempuan Zainab II, Kota Bharu, Kelantan, Malaysia

### **INTRODUCTION**

Complete pathological response occurs in 10-20% of rectal cancer patients who are treated with neoadjuvant concurrent chemoradiation (CCRT) prior to surgical resection.

### **CASE REPORT**

A 46 year old Malay man was diagnosed to have adenocarcinoma of rectum in Jan 2013. Tumor was constricting, long segment and located in the upper rectum until distal sigmoid (10 cm length). Initial trephine proximal transverse colostomy was done and CECT-scan staging showed locally advanced rectosigmoid tumor. He was given neoadjuvant chemoradiotherapy (Xeloda + DXT) aiming to downsize the bulky tumor and subsequently undergo anterior resection with TME.

Macroscopically, no obvious tumor with fibrotic bowel wall at the level of previously documented tumor. Histological examination did not reveal any malignant cells in the rectal wall as well as in the mesorectum. No lymph nodes were identified and vessels in the subserosal fat were thrombosed. Final tumor stage was ypTONOMO. At present clinical outcome was excellent.

### **DISCUSSION**

Current standard of care of patients with locally advanced rectal cancer include the use of neoadjuvant chemoradiotherapy. Minority of patient may achieve a complete pathological response after chemoradiation. Despite this benefit, studies have shown that rectal cancer patients that undergo neoadjuvant CCRT associated with low recurrent rate and improved five-year overall and disease-free survival rates.





**POSTER PRESENTATIONS**

PP14

**EXTRACOLONIC MANIFESTATION OF FAMILIAL ADENOMATOSIS POLYPOSIS:  
MANAGEMENT DILEMMA**

N S Amin<sup>1</sup>, S M Ikhwan<sup>2</sup>, H I M Siti Rahmah<sup>2</sup>, Z Zaidi<sup>2</sup>, M M Faris<sup>2</sup>, W Z W Zainira<sup>2</sup>, S Hassan<sup>2</sup>

<sup>1</sup>Department of Surgery, School of Medical Sciences, Universiti Malaysia Sabah, Sabah, Malaysia

<sup>2</sup>Department of Surgery, School of Medical Sciences, Universiti Sains Malaysia Health Campus, Kubang Kerian, Kelantan, Malaysia

Familial Adenomatous Polyposis ( FAP ) is an autosomal dominant condition characterized by diffuse intestinal polyposis. APC gene mutation is a known predisposition factor for developing colon cancer with disease penetrance up to 100% at the age of 40 years old. Thus, early detection and early intervention are the utmost importance. Surgical intervention towards polyposis within the colon is no more questionable. However, decision for those who presented with polyps elsewhere within the gastrointestinal tract is still controversial as further resection may end up with morbidity. We reported a case of a 49-year-old gentleman with strong family history of FAP, who presented with complained of altered bowel habit for almost 2 years. Further work up done showed multiple polyps from caecum to the rectum with invasive sigmoid cancer. Panproctocolectomy with ileoanal anastomosis was successfully performed and patient subsequently undergone chemo-radiotherapy. Post operative OGDS revealed multiple polyps within stomach and duodenum which were biopsied and showed adenomatous polyps. However patient was not keen for any subsequent surgical intervention. The management of extracolonic manifestation of FAP however still remain debatable in term of extend of surgery and the surgical related morbidity. We reviewed few literature regarding the latest management of extracolonic manifestation of FAP and its associated morbidity and mortality. Close surveillance follow up with histopathological examination is needed to exclude malignant transformation.

**POSTER PRESENTATIONS**

PP15

**LIPOMATOUS CAECAL POLYP CAUSING ILEOCAECAL INTUSSUSCEPTION IN AN ELDERLY  
LADY: A CASE REPORT**

Ikhwan Sani Mohamad, Kenneth Voon Kher Ti, Zaidi Zakaria, Syed Hassan Syed Aziz

Department of Surgery, School of Medical Sciences, Universiti Sains Malaysia Health Campus, Kubang Kerian, Kelantan, Malaysia

Intussusception is an uncommon cause of intestinal obstruction especially in adult. Adult intussusception accounts for only 5% of all cases of intussusceptions.

We presented a case of a 63-year- old lady who presented with 1 week history of right- sided colicky abdominal pain which gradually became generalized, associated with vomiting out bile stained fluids. After series of investigations and worsening condition, emergency exploratory laparotomy was performed and unfortunately ileocolic intussusception was found. The patient underwent right hemicolectomy. Gross specimen dissected showed a large polyp in the caecum with several areas of ulceration on the caecal mucosa. Histopathological report confirmed lipomatous polyps arising from ileocaecal junction. There was no malignancy detected.

Intussusception in adults is a different entity from children; therefore, it warrants a different approach in management. Most recommendations of management are going towards resection of the involved segment without attempt of reduction as the causes of the intussusceptions in adults are usually due to pathological conditions within the involved segment



**POSTER PRESENTATIONS**  
PP16

## **CO-EXISTING ABDOMINAL TUBERCULOSIS AND MUCINOUS ADENOCARCINOMA OF COLON: A CASE REPORT**

S M Ikhwan<sup>1</sup>, L S Bob<sup>1</sup>, A A M Zin<sup>2</sup>, Z Zaidi<sup>1</sup>, S Hassan<sup>1</sup>

<sup>1</sup>Department of Surgery, School of Medical Sciences Universiti Sains Malaysia Health Campus, Kubang Kerian, Kelantan, Malaysia

<sup>2</sup>Department of Pathology, School of Medical Sciences Universiti Sains Malaysia Health Campus, Kubang Kerian, Kelantan, Malaysia

Abdominal tuberculosis and colonic carcinoma are very common but co-existing abdominal tuberculosis and mucinous adenocarcinoma is unusual and is considered a rare entity.

We reported a case of a 47-year old gentleman who was initially referred to us from district hospital with 1 month history of watery diarrhea and significant loss of weight. He denied history of night sweat, chronic cough or any contact with pulmonary tuberculosis patient. Colonoscopy and CT scan confirmed the diagnosis of advanced splenic flexure carcinoma with lung metastasis. Due to bleeding tumour, we proceeded with emergency laparotomy. Intraoperative findings was splenic flexure tumour which infiltrated into the greater curvature of the stomach. Left hemicolectomy, subtotal gastrectomy, gastrojejunostomy and creation of colostomy were performed. Histopathology showed features of both mucinous adenocarcinoma and abdominal tuberculosis.

The cause-effect relationship between these two conditions has been discussed and debatable. Two main postulations have been proposed. Chronic inflammatory mucosal damage due to tuberculosis may initiate a sequence of metaplasia and dysplasia results in neoplastic change. Besides that, carcinoma itself may facilitate the entry of tubercle bacilli with development of secondary infection. Further studies with large sample are needed to detect or explain the association between these two different pathologies.

**POSTER PRESENTATIONS**  
PP17

## **LOWANTERIOR RESECTION FOR ADENOCARCINOM OF RECTAL PROLAPSE**

I Ismaliza , N Amri, W Khamizar  
Hospital Sultanah Bahiyah, Alor Setar, Kedah, Malaysia

Low anterior resection for adenocarcinoma of rectal prolapse

### **CASE REPORT**

This is 73 years old Malay Man who had suffered from rectal prolapse which was irreducible since 1 month prior to presentation & presented to us as case of rectal cancer. At presentation his main complaint was painful rectal bleeding which occur 1-2 days prior to admission. His physical examination revealed there was relaxed anal sphincter & large reddish mass protruding via anal canal. There was a fungating lesion at upper part of mucosa. An incisional biopsy was performed and the histopathological result was adenocarcinoma of rectum. In a case of rectal prolapse, detailed history with accurate diagnosis should be made in order to not missed all rectal cancer cases.



**POSTER PRESENTATIONS**  
PP18

## **AN AUDIT ON SURGICAL INTERVENTION FOR COMPLICATED COLONIC DIVERTICULAR DISEASE IN HOSPITAL MELAKA: 7 YEARS DURATION**

J H Lai, S L Teh, A H Y Amar

Surgical Department, Hospital Melaka, Melaka, Malaysia

### **BACKGROUND**

Complicated diverticular disease often results in surgical intervention. In Hospital Melaka we adopted the same approach. It is about time we have to reflect on our series for surgical audit in this matter.

### **OBJECTIVE**

To determine the outcome of patients underwent surgery for complicated diverticular disease.

### **METHOD**

Retrospective study. Clinical notes of all patients with complicated diverticular disease managed surgically between 1<sup>st</sup> November 2005 and 31<sup>st</sup> December 2012 were analyzed.

### **RESULTS**

Over a period of 85 months, 59 patients were enrolled for the disease. Majority were admitted for bleeding (37.7%, n=22), followed by abscess (35.6%, n=21), perforation (18.6%, n=11) and diverticulitis (6.8%, n=4). Antiplatelet/NSAIDs consumption and history of hypertension were commonly associated with bleeding ( $p=0.007$  and  $0.009$  respectively). Right sided disease (39%, n=23) frequently affected younger patients ( $p=0.000$ ) as compared to pan-diverticular disease (33.9%, n=20) which usually affected older age group ( $p=0.021$ ) and mostly presented with bleeding ( $p=0.000$ ). Hartmann's and Hartmann's like procedure were commonly performed for both left sided and pan-diverticular disease ( $p=0.017$ ,  $p=0.008$ ) whereas right sided disease had higher rate of primary anastomosis (n=19, 82.6%,  $p=0.000$ ). From 31 patients with stoma created, 61.3% (n=19) managed to reverse after a median 5.7 months, with reversal rate being higher at the mean-age of 61.3years ( $p=0.001$ ). Post-operative mortality being 15.3% (n=9), was strongly associated with chronic renal failure, post-operative sepsis, respiratory and cardiovascular complications ( $p=0.001$ ,  $p=0.000$ ,  $p=0.001$  and  $p=0.041$  respectively).

### **CONCLUSION**

Hartmann's and Hartmann's like procedure were preferred choice of surgery and about 60% of them were able to reverse. The mortality rate was comparable and intertwined with end organ failure in Hospital Melaka.



**POSTER PRESENTATIONS**  
PP19

## **3 YEARS OF EXPERIENCE WITH FISTULA-IN-ANO REPAIR IN HOSPITAL TENGGU AMPUAN AFZAN, KUANTAN, PAHANG: A SURGICAL CHALLENGE**

M Salehudin C Z, Azmi M Nor, Fadel S

Colorectal Unit, Department of Surgery, Faculty of Medicine, International Islamic University Malaysia, Kuantan, Pahang, Malaysia

### **PURPOSE**

Fistula-in-ano is a benign anorectal disease which always poses a big dilemma to the surgeons because of their significant recurrent rate and longer healing duration following surgery. We report our experience in the last 3 years with various fistula surgeries in our center.

### **MATERIALS AND METHODS**

Retrospective review of patient's medical records that underwent fistula surgery has been made. A total of 40 patients underwent fistula repair under elective operation list identified. Demographic data of patients were assessed. Patient subjected to endoanal ultrasound prior to the surgery to determine types of fistula based on Park's classification. Follow up was made post-operatively in a scheduled timing to see the progress, duration of healing, and recurrence or persistent of the disease.

### **RESULTS**

Mean age of the patient presented to our center was 43.5 year old. Intersphincteric and transphincteric type of fistula account 42.5% and 30% respectively. 2 most common methods of fistula repair were core fistulectomy and LIFT which account for 52.5% and 30% respectively. 75% of patients achieved primary healing after the procedure. Mean healing duration of those who underwent core fistulectomy was 7 weeks and LIFT was 16 weeks. 28.6% of patients subjected to core fistulectomy failed to fully recover either had persistent or recurrence of the disease whereas LIFT had 25% of failure rate.

### **CONCLUSIONS**

Even though we managed to achieve significant success rate cumulatively, persistent or disease recurrence still imposed the challenge toward patient's management of the disease in a long run. However, core fistulectomy revealed shorter time of recovery as compared to LIFT. Therefore, further prospective study is recommended to look into this method in term of rapid recovery with minimal morbidity.



**POSTER PRESENTATIONS**  
PP20

## **UNUSUAL PRESENTATION OF ISCHIORECTAL (HORSESHOE TYPE) ABSCESS**

Noor Ezmas Mahno<sup>1</sup>, David Ong<sup>2</sup>, Fadeel Shabeeb<sup>1</sup>, Azmi Md Nor<sup>1</sup>

<sup>1</sup>International Islamic University of Malaysia, Kuantan, Pahang, Malaysia

<sup>2</sup>Hospital Tengku Ampuan Afzan, Kuantan, Pahang, Malaysia

### **INTRODUCTION**

Ischiorectal abscess is the second most common of anorectal abscess. If it spread further to right and left ischiorectal space, it will form a horseshoe's shape.

### **CASE**

This is a 21 years old Chinese gentleman with 4 days history of colicky lower abdominal pain and low grade fever. No significant past medical history. Clinically, tenderness felt over left iliac fossa, palpable bladder with boggy tenderness felt per rectal and rectal tenderness at 9 o'clock position. Perianal examination looks normal. Blood investigation showed leucocytosis with predominantly neutrophils. Urine examination and abdominal X-ray was unremarkable. Ultrasound abdomen initially was unremarkable but repeated ultrasound on day 3 of admission showed an ill-defined hypoechoic lesion seem to be arising from the rectal wall. Endoanal ultrasound showed horseshoe ischiorectal abscess up to the level of prostate. Subsequently, we proceed with examination under anaesthesia and drainage of abscess on the 7th of January 2014. No perianal fistula seen. Proctoscopy examination was normal. We made 2 separate incisions deep into both right and left ischiorectal space with a communicating penrose drain. Antibiotic given for 1 week course. Postoperative course was uneventful and wound healed well.

### **DISCUSSION**

Horse shoe type of ischiorectal abscess needs a different surgical approach than simple perianal abscess. A penrose drain was kept to ensure complete drainage of the abscess. Drainage should be prompt to prevent further complication of fistula, necrotizing infection, gangrene and sepsis. Early presentation may be subtle, thus endoanal ultrasound is a better tool for proper diagnosis and management.

### **CONCLUSION**

Proper tool is important to lead us for proper diagnosis especially when the clinical presentation is unusual.



**POSTER PRESENTATIONS**

PP21

**MESENTERIC CYST OF DESCENDING COLON: A RARE SUBTYPE**

Noor Ezmas Mahno<sup>1</sup>, David Ong<sup>2</sup>, Fadeel Shabeeb<sup>1</sup>, Azmi Md Nor<sup>1</sup>

<sup>1</sup>International Islamic University of Malaysia, Kuantan, Pahang, Malaysia

<sup>2</sup>Hospital Tengku Ampuan Afzan, Kuantan, Pahang, Malaysia

**INTRODUCTION**

Mesenteric cyst is rare and can occur at any age. Usually, it was found incidentally unless the cyst became complicated. Mostly, it affected the mesentery of the small bowel.

**CASE**

This is a 73 years old lady with incidental finding of abdominal mass during gynae follow-up for her uterovaginal prolapsed. She is otherwise asymptomatic with no significant past medical history. Clinically, she is a medium built lady with a huge palpable left lumbar mass, which was soft, mobile and not indentable. Contrasted enhanced abdominal CT scan showed a well-defined single cystic lesion. CEA was normal. Colonoscopy showed multiple colonic diverticulosis with external compression at the descending colon. We proceed with exploratory laparotomy and complete excision of the cystic mass on 29th of October 2013. Intraoperatively, there was a uniloculated cyst arising from the mesentery of the descending colon measuring about 12 x 10cm. Upon opening, the cyst contained clear fluid. Histology report showed the cyst wall lined by endometrium like epithelium with no evidence of malignancy. Postoperative course was uneventful with no recurrence.

**DISCUSSION**

Mesenteric cyst is most likely to occur congenitally due to incomplete fusion of mesothelial-lined peritoneal surface. Usually presented in children or young adult. Pre-operative diagnosis can be difficult due to its rarity and no specific clinical presentation. Sometimes, resection of adjacent organ may be necessary to exclude malignant alteration and to prevent complication.

**CONCLUSION**

Although simple mesenteric cyst is rare, it must be considered as a differential diagnosis when dealing with cystic lesion of the abdomen. The treatment of choice is a complete surgical excision of the cyst.

**POSTER PRESENTATIONS**

PP22

**GANGRENOUS COLON : POLYARTERITIS NODOSA OF THE GASTROINTESTINAL TRACT**

F J Ruhi<sup>1,2</sup>, I Sagap<sup>2</sup>

<sup>1</sup>Universiti Sains Islam Malaysia, Kuala Lumpur, Malaysia

<sup>2</sup>University Kebangsaan Malaysia, Kuala Lumpur, Malaysia

Polyarteritis nodosa (PAN) is a systemic necrotizing vasculitis preferentially targeting medium-sized arteries and not associated with glomerulonephritis or small vessel involvement. Clinical manifestations of PAN are multisystemic. Peripheral nerve and skin are the most frequently affected tissues. Involvement of the gastrointestinal tract, kidneys, heart, and central nervous system is associated with higher mortality.

We illustrate a case of 39 years old Chinese technician whom presented with gangrenous colon. Histopathological examination revealed as vasculitis changes likely due to polyarteritis nodosa. He was combined managed with rheumatology team. Further investigations noted all immunological and Hepatitis screenings were negative. He is treated with high dose immunosuppressant and still undergoing treatment. The etiology, pathology, symptomatology and surgical management of this condition are reviewed and discussed



**POSTER PRESENTATIONS**  
PP23

**EXTENSIVE COLONIC ISCHEMIA – REPORT OF A CASE**

Sarmukh S<sup>1</sup>, M O Myint<sup>2</sup>, Shaker A H<sup>2</sup>

<sup>1</sup>Hospital Serdang, Selangor, Malaysia

<sup>2</sup>University Putra Malaysia, Serdang, Selangor, Malaysia

**INTRODUCTION**

Intestinal ischemia especially colonic ischemia is a relatively uncommon cause of abdominal pain. The abdominal pain caused by intestinal ischemia is not proportional to the physical examination findings. The majority of patients with ischemic colitis can be treated medically, but approximately 20% of the patients clinically deteriorate to develop peritonitis and sepsis, necessitating surgical intervention with an associated 60% mortality rate.

**CASE REPORT**

A 39 years old Burmese gentleman presented with generalized abdominal pain for 1 month associated with nausea , vomiting and watery yellowish stool sometimes mixed with fresh blood. On examination patient was severely dehydrated . Abdominal examination revealed generalized tenderness with guarding . Chest & abdominal X-ray showed no free air and no dilated bowel loops . CT abdomen showed matted bowel loops in right lower quadrant. With provisional diagnosis of bowel perforation , proceeded with exploratory laparotomy and operative findings were thick and foul smelling pus in peritoneal cavity , few greyish white ischaemic patches over proximal colon until splenic flexure, necrosis of most of greater omentum. Omentectomy and ileostomy was done. Postoperative diagnosis was sealed colonic perforation due to ischaemic colitis. Relaparotomy was done and showed distal small bowel, ascending colon, transverse colon and proximal descending colon was gangrenous. All gangrenous bowels were resected and covering ileostomy was performed. Patient did not recover from sepsis and finally expired on post op day 4 with multi organ failure.

**CONCLUSION**

Extensive colectomy (nearly subtotal colectomy) may be better option for first laparotomy in this patient's condition if the case was reviewed retrospectively. However absence of other obvious medial comorbidity, unusual presentation and very unstable patient's condition made management not easy and straight.



**POSTER PRESENTATIONS**  
PP24

**ACUTE COLONIC PSEUDO-OBSTRUCTION (OGILVIE'S SYNDROME) –  
A RARE COMPLICATION IN POST TAHBSO AND SIGMOIDECTOMY**

Sarmukh S<sup>1</sup>, M O Myint<sup>2</sup>, Salleh M<sup>2</sup>, Shaker A H<sup>2</sup>

<sup>1</sup>Department of Surgery, Hospital Serdang, Selangor, Malaysia

<sup>2</sup>Department of Surgery, University Putra Malaysia, Selangor, Malaysia

**INTRODUCTION**

Acute colonic pseudo-obstruction as a syndrome was first described by Ogilvie in 1948. It is characterized by colonic dilatation in the absence of mechanical obstruction or any obvious causes of paralytic ileus. The syndrome's pathogenic mechanism remains unknown. Until 1986 only 400 cases had been reported. It can also be idiopathic in a small percentage of patients.

**CASE REPORT**

A 48 year old Malay lady, nulliparous was first seen in O&G clinic for prolonged menses for the past 1 year. Patient complaint of passing out bloody vaginal discharge with foul smelling for past 4 months, with prolonged and irregular menses and have LOA and LOW. After our work up noted the diagnosis was endometrial Carcinoma with cervical involvement. Proceeded with TAHBSO and supracolic omentectomy. Because of involvement of the sigmoid colon, sigmoidectomy done. Post operatively day 3, patient developed severe sepsis. In view of anastomotic leak we proceeded with CT abdomen shows no features of anastomotic leak but dilated large bowel with some narrowing at the presumed anastomotic site at the rectum. Impression was Mechanical obstruction. We proceeded with the colonoscopy to look at the anastomotic site. The finding was the whole colon is dilated (without any insufflation). No area of narrowing seen throughout the whole colon, especially in previous anastomotic site. Our diagnosis was Pseudo-obstruction of colon as there is no evidence of mechanical obstruction and a flatus tube inserted for decompression of dilated colon.

**CONCLUSION**

We believe that OS, though uncommon, is a diagnosis to consider when investigating patients who have recently undergone TAHBSO and sigmoidectomy. Colonoscopy at the earliest possible time can be of both diagnostic and therapeutic value as it provides: a) exclusion of obstruction and establishment of the diagnosis among other possible causes of colonic dilatation and b) successful decompression of the colon.





**POSTER PRESENTATIONS**  
PP25

**PREOPERATIVE CARCINOEMBRYONIC ANTIGEN;  
A PROGNOSTIC INDICATOR OF TUMOR GRADE**

Satkunan M, D Z Andee, Z Zaidi, S Hassan

Department of Surgery, School of Medical Sciences, Universiti Sains Malaysia Health Campus, Kubang Kerian, Kelantan, Malaysia

**BACKGROUND**

Colorectal cancer (CRC) is the commonest gastrointestinal malignancy worldwide. It continues to be a threat to patients and pose challenges to surgeons and oncologists. There has been a lot of research done to identify and prognosticate patients with CRC. The use of serum carcinoembryonic antigen (CEA) in determining the prognosis of these patients is widely advocated. Though the overall prognosis of CRC is multifactorial, the histological grading plays a significant role. The aim of this study is to show the predictive value of pre- operative CEA in determining tumor grade in patients with CRC.

**METHODS**

A total of 21 patients diagnosed to have CRC in 2013 were included in this retrospective analysis. Pre- operative CEA, histopathological reports and overall staging of these patients were reviewed. Statistical analysis were done to derived associations between the above mentioned variables with emphasis on tumor grade and CEA correlations in patients who had undergone surgery for CRC

**RESULTS**

A total of 21 patients were recruited, of which 90% showed moderately differentiated adenocarcinoma ( 19/21) while 5% (1/21) had well differentiated adenocarcinoma and 5% (1/21) has signet ring carcinoma. CEA was elevated in 62% of cases (13/21). Statistical analysis was done using SPSS software and there was statistically significant association between raised CEA and resultant histological tumor grade ( $p= 0.27$ ).

**CONCLUSION**

Our review indicates that there is association between pre- operative CEA and tumor grade. We found that an elevated CEA was associated with a higher tumor grade. We therefore suggest that a raised CEA is a significant prognostic indicator of tumor grading and hence a pre- operative prognostic marker.

**KEY WORDS**

Colorectal cancer, carcinoembryonic antigen, tumor grade

**POSTER PRESENTATIONS**  
PP26

**RECURRENT COLORECTAL CANCER AT STOMA SITE WITH PALLIATIVE STENTING OVER  
STOMA: A CASE REPORT**

Syafiq H M M, Fahmey M S, Imran A K

Department of Surgery, Hospital Seberang Jaya, Seberang Prai, Penang, Malaysia

Recurrent metachronous colostomy site carcinomas are rare with only ten cases reported in the world literature. Here we would like to report on a patient who had a Paul Mikulicz procedure done for obstructed sigmoid cancer. He subsequently presented again a year and a half later with intestinal obstruction which was due to a recurrent cancer at the stoma site. Colonic stenting was done over the stoma as a treatment modality along with palliative care.



**POSTER PRESENTATIONS**

PP27

**COLONIC ADENOCARCINOMA METASTASIS TO OVARIES OR PRIMARY OVARIAN TUMOURS WITH COLON METASTASIS: HOW TO DETERMINE IT?**

Syafiq H, Fahmey M S, Imran A K

Department of Surgery, Hospital Seberang Jaya, Seberang Prai, Penang, Malaysia

Colorectal cancer often metastasises via lymphatic drainage followed by vascular drainage and transcoelomic routes. In contrast, ovarian tumours commonly spread via local extension followed by lymphatic invasion, intraperitoneal implantation and hematogenous dissemination. We report a case of a young lady who presented with peritonitis in sepsis. She was diagnosed to have primary colonic adenocarcinoma metastasis to ovary. This article focuses on colon adenocarcinoma, the difficulties in intraoperative management and the histological findings in confirming the diagnosis.

**POSTER PRESENTATIONS**

PP28

**KANA FRUIT: A RARE CAUSE OF SMALL BOWEL OBSTRUCTION**

K N Tan, Nil Amri M Kamil, Wan Khamizar W Khazim

Hospital Sultanah Bahiyah, Alor Setar, Kedah, Malaysia

Small bowel obstruction caused by foreign body ingestion is rare; it represents less than 6% of all small bowel obstruction cases. Many items have been reported as responsible, but there are no reports implicating Kana fruit. We describe a rare case where a 4 years boy presented with symptoms mimicking acute appendicitis or intussusception but turned out to be mechanical small bowel obstruction secondary to a Kana fruit. A high index of suspicion of foreign body ingestion should be kept in mind as a possible differential diagnosis when patients present with small bowel obstruction, especially in children and patients with psychiatric illnesses.

**POSTER PRESENTATIONS**

PP29

**PRIMARY COLONIC LYMPHOMA PRESENTING AS PERFORATED VISCUS**

K N Tan<sup>1</sup>, H L Hoo<sup>2</sup>, Nil Amri M Kamil<sup>1</sup>, Wan Khamizar W Khazim<sup>1</sup>

<sup>1</sup>Hospital Sultanah Bahiyah, Alor Setar, Kedah, Malaysia

<sup>2</sup>Hospital Enche' Besar Hajjah Khalsom, Kluang, Johor, Malaysia

Primary colonic lymphomas are rare tumours of the gastrointestinal tract and accounts for only 0.2-1.2% of all colorectal malignancies. Most authors reported caecum being the most common site for colonic lymphoma (78%), followed by rectum. We describe a rare case where a 64 years man presented with peritonitis secondary to perforated primary descending colonic lymphoma.



**POSTER PRESENTATIONS**

PP30

## **A CASE OF SIGNET-RING CELL CARCINOMA OF CAECUM PRESENTED LIKE ACUTE APPENDICITIS**

K N Tan<sup>1</sup>, H L Hoo<sup>2</sup>, Nil Amri M Kamil<sup>1</sup>, Wan Khamizar W Khazim<sup>1</sup>

<sup>1</sup>Hospital Sultanah Bahiyah, Alor Setar, Kedah, Malaysia

<sup>2</sup>Hospital Enche' Besar Hajjah Khalsom, Kluang, Johor, Malaysia

Up to 99% of signet-ring cell carcinomas of gastrointestinal tract are found in the stomach. Colorectal signet-ring cell carcinoma is rare with an incidence 0.1-2.4% of all colorectal cancer. Most of the reported cases were encountered in late adulthood with mean age of diagnosis at about 60 years; presentation at an early age was rare. Being common in rectum and right hemicolon, the common symptoms are rectal bleeding and small bowel obstruction. We describe a case of right iliac fossa pain which mimicked an acute appendicitis in a 40 years lady, to highlight this diagnosis and its histological features.

**POSTER PRESENTATIONS**

PP31

## **A PREVALENT DISEASE OFTEN OVERLOOKED**

Nadia Nafasha Baharudin, K N Tan, Nil Amri M Kamil, Wan Khamizar W Khazim

Hospital Sultanah Bahiyah, Alor Setar, Kedah, Malaysia

Lower gastrointestinal bleeding is the bleeding distal to the ligament of Treitz and ranges from occult loss to massive hemorrhage. In children and young patients, the most frequent causes are juvenile polyps, Meckel diverticula, and intussusception; in adult ages are the anal fissure, hemorrhoid, colonic diverticulosis, angiodysplasia and neoplasia; we must also include the intestinal tuberculosis, typhoid fever, and amoebic colitis. We report a case of recurrent per rectal bleeding in a 54 years male prisoner who was treated for his initial 2 visits for anal fissure and hemorrhoid respectively. His diagnosis was only known on his 3rd visit in the light of histological examination of a colonoscopy biopsy.

**POSTER PRESENTATIONS**

PP32

## **RECTAL FOREIGN BODY: SURPRISE BEYOND THE CUP**

K N Tan, Nil Amri M Kamil, Wan Khamizar W Khazim

Hospital Sultanah Bahiyah, Alor Setar, Kedah, Malaysia

Rectal foreign bodies in adults are not an uncommon presentation to the emergency department and are mostly associated with increased incidence of homosexuality and anal auto-erotism. Nature of rectal foreign bodies is limited only by the imagination of the patient concerned. Their textures, sizes, shapes, and locations are critical considerations before removal and impacting on retrieval approaches. Many techniques have been described for removal and various theories have been put forward to explain the mechanics of the procedure. Extraction by fiberoptic rectosigmoidoscope is advocated as the treatment of choice but is not always possible. Glass objects require technical considerations to minimize morbidity and may necessitate surgical extraction. We report a middle-aged unmarried man presenting with a retained glass cup in the rectum where a new technique had been employed and another foreign body had been found beyond the cup. Literature review found no other reports of rectal foreign body removal by this method. A high index of suspicion of a second rectal foreign body should be kept in mind when patients present with a rectal foreign body.



**POSTER PRESENTATIONS**  
PP33

## **LAPAROSCOPIC ASSISTED TWO PORTS APPENDICECTOMY FOR FREE APPENDIX “ANY SURGICAL MEDICAL OFFICER CAN DO”**

Mutyala Vinod Kumar, Yiu Maeng Tang, Choon Woon Ngo  
Hospital Duchess of Kent, Sandakan, Sabah, Malaysia

### **BACKGROUND**

Appendicectomy is a very common emergency procedure performed by medical officers in Government hospitals in Malaysia.

### **OBJECTIVE**

We present our experience with clinically-proven obstructive and non perforated appendicitis, performed by a laparoscopic assisted two ports appendicectomy for free appendix, and its feasibility in government hospitals with basic laparoscopic equipments.

### **METHODS**

Retrospective analysis through hospital records. Appendicectomy was performed by a laparoscopic assisted two ports method. One 5mm port inserted transumbilically, and another 10mm port in the right iliac fossa depending upon the location of the base of the appendix.

### **RESULTS**

Throughout the year 2013, a total of 239 appendicectomies were done. Total of 55 cases were done laparoscopically, with 18 cases proceeded with laparoscopic assisted two ports appendicectomy. The mean duration for the laparoscopic assisted two ports appendicectomy was 48 minutes. The mean duration of length of hospital stay post operatively was 1.3 days. Only one patient had prolonged stay due to ileus, which was managed conservatively.

### **CONCLUSION**

Most of the appendicitis we have encountered is non-retrocaecal in nature, in contrary to textbook description, where the data is from cadaveric samples. We conclude that laparoscopic assisted two ports appendicectomy can be done safely by medical officers with basic laparoscopic skills and proper apprenticeship. This simple approach can be converted to total intracorporeal by inserting additional port or to open appendicectomy when required. This approach has the advantage of full laparoscopic inspection of other intra-abdominal and pelvic organs. In an event of white appendix, it would not be removed and will be further investigated by colonoscopy, especially in the elderly.